COUNTWAY LIBRARY
HC 4Q1V 5

UTERINE TUMORS

CHARLES C. NORRIS

24. N.

BOSTON
MEDICAL LIBRARY
8 THE FENWAY

HARPER'S
MEDICAL MONOGRAPHS

UTERINE TUMORS

Harper's Medical Monographs

PRACTICAL MONOGRAPHS FOR THE PRACTITIONER

ADVISORY EDITORS

W. C. ALVAREZ, Rochester, Minn.
G. E. BREWER, New York
G. W. CRILE, Cleveland
N. B. FOSTER, New York
L. HAMMAN, Baltimore
A. T. OSGOOD, New York
E. A. PARK, Baltimore
H. C. TAYLOR, New York
G. B. WEBB, Colorado Springs
U. J. WILE, Ann Arbor

UTERINE TUMORS

By CHARLES C. NORRIS, M.D.

There have previously appeared in this series:

SYPHILIS, *by* Charles C. Dennie, M.D., *Kansas City*
ANGINA PECTORIS, *by* Harlow Brooks, M.D., *New York*
DIABETES MELLITUS, *by* William D. Sansum, M.D., *Santa Barbara*

Volumes on the following subjects are now in the course of preparation and will be published in the near future. They will be uniform with this work.

CARE OF TRAUMATIC AND INDUSTRIAL CONDITIONS
by Clay Ray Murray, *New York*
ASTHMA AND HAY FEVER, *by* Robert A. Cooke, *New York*

RALPH G. STILLMAN
Managing Editor
8 West 16th Street, New York, N. Y.

Harper's Medical Monographs

UTERINE TUMORS

By

CHARLES C. NORRIS, M.D.

Professor of Gynecology and Obstetrics and Director of the Department, University of Pennsylvania; Gynecologist and Obstetrician, Hospital of the University of Pennsylvania, Henry Phipps Institute of the University of Pennsylvania, and Radiologic Department of the Philadelphia General Hospital; Gynecologist, Children's Hospital, Philadelphia; Consultant Obstetrician Philadelphia Maternity Hospital

HARPER & BROTHERS PUBLISHERS

New York *and* London

MCMXXX

24. N. 118.

UTERINE TUMORS
COPYRIGHT, 1930, BY HARPER & BROTHERS
PRINTED IN THE UNITED STATES OF AMERICA
FIRST EDITION
C-E

CONTENTS

Chapter		Page
	Preface	ix
I.	Cervical Polyps	1
II.	Carcinoma and Other Malignant Tumors of the Cervix	10
III.	Carcinoma of the Body of the Uterus	78
IV.	Myoma Uteri	110
V.	Sarcoma and Allied Tumors of the Body of the Uterus	196
VI.	Tumors of the Chorion	220
	Index	249

ILLUSTRATIONS

Figure		Page
I.	Cervical Polyps	3
II.	Normal Cervix	12
III.	Cervix Showing the Results of Laceration and Eversion	14
IV.	Carcinoma of the Cervix	22
V.	Carcinoma of the Cervix	24
VI.	Lymphatic Drainage from the Uterus	27
VII.	Adenocarcinoma of the Fundus	80
VIII.	The John G. Clark Test for Carcinoma of the Fundus	99
IX.	Method of Maintaining Radium-bearing Rubber Tube in the Uterus	105
X.	Common Varieties of Uterine Myomata	117
XI.	Parasitic or Wandering Uterine Myoma	119
XII.	The John G. Clark Trimanual Method of Eliciting Fluctuation	144
XIII.	Diffuse Adenomyoma of the Uterus	186
XIV.	Hydatidiform Mole	223

PREFACE

The uterus is one of the most frequent sites in the human body for the development of tumors. The treatment of these neoplasms constitutes a large part of the practice of those specializing in gynecology. Whereas the general practitioner may not possess the experience or facilities for the treatment of the more important new growths of the uterus, the early recognition of these and the advantages and disadvantages of the different forms of treatment are of vital importance to him and to many of his patients.

In the laboratory of gynecological and obstetrical pathology at the Hospital of the University of Pennsylvania during the last twenty years, 13,630 gynecological specimens have been examined. Of these, 3,607, or 26 per cent, have been uterine tumors. Uterine myomata are the most frequent tumors occurring within the peritoneal cavity, and it is questionable if they are not the most frequent important new growths occurring in man, regardless of sex or site of location. Carcinoma of the cervix is the most frequent malignant new growth occurring below the waistline. Post-menopausal

bleeding is more likely to result from carcinoma of the uterus than from all other causes combined.

Not only is the occurrence of carcinoma of the cervix and fundus extremely common, but both are highly malignant, the ultimate five-year salvage being about 20 to 25 per cent in the former, and 35 to 40 per cent in the latter. Early cases give better results, but these are infrequently seen. Prophylaxis and early diagnosis are the points stressed in all cancer work, and in practically every paper relating to the treatment of this disease. In the vast majority of cases the recognition of the condition, or at least the suspicion that carcinoma may be present, and the responsibility of securing early and efficient treatment for the patient, rest upon the general practitioner.

The two most frequent causes for delay in the treatment of these cases are the non-painful character of the symptoms of carcinoma both of the cervix and of the fundus, and the failure on the part of the medical adviser to make a thorough examination. The average medical practitioner is fully competent to make a pelvic examination, and if he is not, there is no excuse for his not recognizing his limitations and certainly recognizing that certain symptoms, such as atypical bleeding or leucorrhea require investigation by some one who is competent. With these points being more and more stressed in our medical schools, all general prac-

titioners should recognize, or at least be suspicious of such cases, and a higher proportion of cases of early cervical carcinoma should be recognized.

With the more general knowledge of the value of the John G. Clark test, and of the reliability of diagnostic curettage, a greater proportion of fundal carcinoma should be detected in the early stage. The general practitioner of the future, and most of those of the present age, should from his reading and visits to gynecological clinics, keep in touch with the simpler refinements of diagnostic methods. In the cases of cervical carcinoma he should be aware of the importance of prophylaxis, which is attained by both immediate and late cervical repair, and be capable of employing the electrocautery for the eradication of cervicitis due to minor lacerations and eversions. If at the present day the general practitioner feels himself incompetent upon these points, he should not attempt to treat women suffering from such conditions.

In the following pages the diagnostic features of the varying uterine tumors have been emphasized, and the tests necessary for their detection during their early stages have been stressed. In this volume major operative technique has been largely omitted. An endeavor has, however, been made to point out the most satisfactory forms of treatment for the various uterine tumors and the indications and contra-indications to their employment. The ad-

vantages and disadvantages of irradiation in the treatment of both benign and malignant lesions have been dealt with in some detail.

Statistics make tiresome reading and are of little value unless carefully and rigidly analyzed. The results secured by the treatment employed in the Gynecological Division of the Department of Obstetrics and Gynecology at the Hospital of the University of Pennsylvania have been quoted more or less extensively because of my familiarity with them and because careful follow-up results are available. The vast literature pertaining to uterine tumors has been largely omitted, due to lack of space, although important articles have been freely drawn upon. Robert T. Frank's monumental work, entitled *Gynecological and Obstetrical Pathology* has been largely consulted, and the valuable work of George Gray Ward and his staff at the Woman's Hospital of New York, and the careful studies of Thomas S. Cullen and his co-workers at the Johns Hopkins Hospital have been extensively utilized. I also wish to acknowledge my indebtedness to William P. Graves and to Brooke M. Anspach for the material drawn upon from their splendid works on gynecology. Acknowledgment is also due to the authors of Veit's *Handbuch* and many other carefully written works too numerous to mention.

CHARLES C. NORRIS

Philadelphia, Pa.

UTERINE TUMORS

CHAPTER I

CERVICAL POLYPS

CERVICAL polyps are common tumors and may spring from any portion of the cervix, but most frequently are found in the canal. They vary in size from that of a small pea to an English walnut. As a rule their color is the same as that of the cervix or the cervical mucosa, but as the result of pressure, infection, degeneration, necrosis, or changes in the blood-supply they may become red, purple, brown, or black. They may be sessile or pedunculated.

Cervical polyps are usually one or two centimeters in length and somewhat smaller in breadth, and generally present at the external os. In extreme cases, however, the polyp may be so large, or its pedicle may be so long, as to protrude from the vulva, whereas in other instances the tumor may be small and completely concealed within the cervical canal.

Both single and multiple forms of polyp occur. Multiple tumors are by no means infrequent, and when they occur, one of the growths is usually larger than the others. As these excrescences are in

reality localized hypertrophies, they are composed of cervical tissue and have the same epithelial covering as the parts from which they spring. As the tumors increase in size this surface covering often becomes thinned out or even desquamated. Polyps which are covered by mucosa are more susceptible to infection and other pathologic changes than are those which are invested in squamous epithelium. Areas of actual erosion are common.

The stroma is composed of fibrous connective tissue, and is more or less interwoven with cervical glands. The number of glands varies markedly in different specimens—some tumors are honeycombed with glands, whereas in others only a few are present. Cystic and other degenerations frequently take place, due to infections, pressure, and vascular derangement. The resulting histologic pictures vary greatly, and their exact character can be determined only as the result of careful study. Reduplication of the epithelium, localized areas of thickening and dipping down of the squamous epithelium, alterations in the size and shape of the glands, and an atypical appearance of both the squamous and the columnar epithelium are of frequent occurrence, and may be suggestive of carcinoma.

Malignant changes, either carcinomatous or sarcomatous, are infrequent, occurring in less than 1

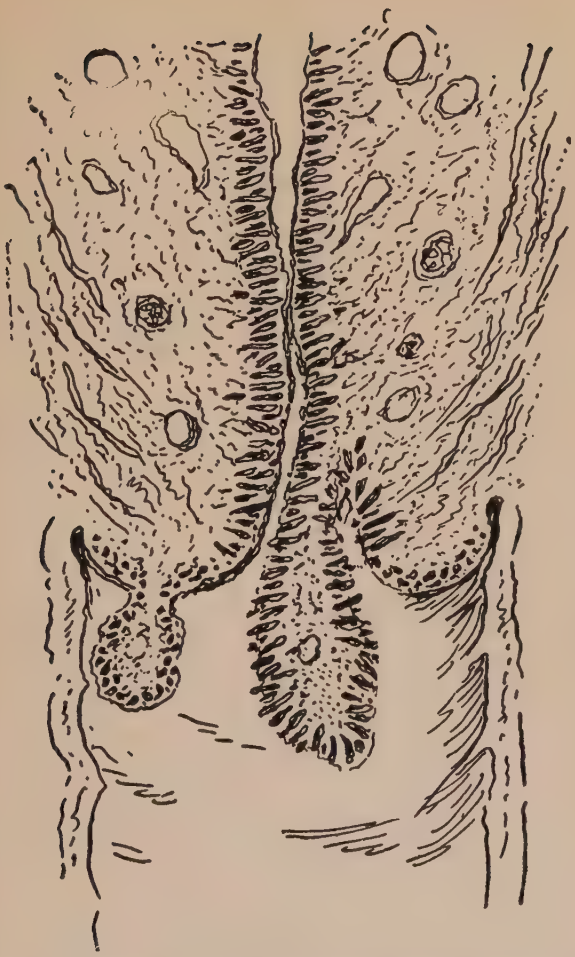

FIG. 1.—*Cervical polyps.* The smaller tumor originating from the portio is covered by squamous epithelium and the polyp springing from the canal is invested by the high columnar epithelium normally situated in this locality.

per cent of cervical polyps, the sarcomatous variety being extremely rare. For purposes of prognosis and in order that proper treatment may be instituted, a histologic examination of the base of the pedicle, as well as of the body of the tumor, should be made. Malignant degeneration may originate in adjacent structures and invade the polyp by extension, or the reverse may occur. Such extension generally occurs through the lymphatics, but contact implantation is not unknown.

Symptoms.—Cervical polyps may be practically devoid of symptoms, but in the majority of cases atypical bleeding and leucorrhea eventually occur. The tumors grow slowly, except when malignancy or pregnancy exists. The bleeding is usually slight and menorrhagic in type, but in some cases the hemorrhage is pronounced and may lead to severe secondary anemia, with its accompanying symptoms. When degeneration or erosion occurs, a slight metrorrhagia is not infrequent, and in some instances may exhibit a tendency to follow trauma. An increase in the amount of the normal cervical secretion is generally present.

When pressure is exerted upon the cervical mucosa, or when infection or an erosion has occurred, a definite leucorrhea develops. This consists of a thick, tenacious, yellowish or brownish discharge,

which may be blood streaked. If the polyp undergoes necrosis, the discharge emits a foul odor.

Polyps are more frequent after forty years of age, and are relatively rare before the age of twenty. They are common during the child-bearing period, but not infrequently occur after the menopause. During pregnancy they grow more rapidly, and are then prone to exhibit more pronounced symptoms.

Parity apparently plays no definite part in the etiology of cervical polyps, since the tumors are relatively as frequent in nulliparæ as in multiparæ.

Vaginal examination often discloses the tumor protruding through the external os, but the growth may sometimes be concealed entirely within the cervical canal, and be detected only after the cervix has been dilated. The external os is frequently more or less dilated, and the lesion may often be palpated as a soft, somewhat movable, oval tumor. The uterus and adnexa are usually normal. Association with myomata is not infrequent, but is of less common occurrence than in polyps of the body of the uterus.

Diagnosis.—This is, as a rule, easily made. Care must, however, be taken to exclude carcinoma. It should be borne in mind that cervical polyps are not only common, but may manifest no symptoms, and that other lesions also may be present. Unless

this is done, the bleeding or discharge may be attributed to the polyp, and a more serious condition be overlooked. The symptoms often suggest carcinoma, especially when they develop during or following the menopause. Due consideration must be given to the fact that polyps may undergo malignant degeneration, although this condition is infrequent. The friable, necrotic character and rapid growth of a papillary cervical carcinoma usually distinguish it definitely from a polyp. Submucous myomata may simulate polyps. Myomata are generally larger than polyps, are usually associated with myoma in the body of the uterus, and are firmer to the touch.

Treatment.—All polyps should be removed. Because of their tendency to be multiple or to be combined with carcinoma, a general anesthetic should be employed. This will permit a thorough exploration of the cervical canal to be made, which is essential in every case. If the polyp is single and pedunculated, it may be twisted from its base. The canal should be dilated, a search for other polyps made, followed by dilatation and curettage. It may occasionally be necessary to split the cervix in order to obtain satisfactory exposure and facilitate the polypectomy. If the polyp is sessile, it should be excised, and the incision closed with catgut. All tissue removed, including the curetting, should be

examined under the microscope, and if malignancy is found to be present, appropriate treatment should be instituted at once.

FIBROMYOMATA OF THE CERVIX

These tumors occasionally occur in the cervix. The body of the uterus may be normal, or a similar type of tumor may be present here. Compared to fibromyomata of the body of the uterus, cervical fibromyomata are infrequent, and constitute about 4 per cent of all uterine myomata. These growths are encapsulated neoplasms, and are similar in general histologic characteristics to those of fibromyomata of the body of the uterus, except that the amount of fibrous tissue is usually greater than in tumors originating in the fundus. Glandular structures may be present in the tumor, and adenomyomata are not infrequent. They may be submucous, interstitial, or intraligamentous in character, according to their location. In the adenomatous variety the growth is frequently pedunculated. In the submucous variety the external os and cervical canal are dilated, and as a result of interference with the blood supply and exposure to infection, the tumors often undergo various forms of degeneration, necrosis being one of the most frequent. The interstitial tumors often become intraligamentous, and may exert pressure on the ureter. In some

instances the intraligamentous neoplasms become separated from the cervix and derive their entire blood supply from the adjacent structures.

Cervical myomata vary greatly in size, and may be so massive as to interfere with labor. When present in conjunction with fundal tumors, they may seriously complicate the ordinary hysteromyomectomy, and require careful dissection. The fact that the position of the ureter is often distorted makes the likelihood of its ligation or severance not improbable unless special care is exercised. Since the submucous tumors are often infected, the dangers of panhysterectomy are enhanced, and when such a combination is present, a vaginal myomectomy should precede the abdominal hysterectomy, and a sufficiently long interval between the two operations should be allowed to lapse to eradicate the infection.

Cervical fibromyomata may remain latent, or produce a variety of symptoms. In the early stage, the submucous variety, a moderate amount of leucorrhea may be present, due to irritation and pressure upon the mucosa of the cervix; later, if infection and necrosis develop, the flow of leucorrhea is augmented, and the discharge becomes darker and malodorous. Interstitial tumors that extend outward between the layers of the broad ligament frequently exert pressure upon the ureter, and give

rise to corresponding symptoms. Pressure upon the bladder or rectum may also arise. In some instances the tumor may be so massive as practically to block the pelvis and give rise to edema of the lower extremities. Cervical myomata rarely cause menstrual disturbances, although irregular hemorrhages may result, especially when the submucous variety or when necrosis is present. Pain is rarely a prominent symptom, unless pressure is being exerted upon adjacent structures.

Treatment.—Vaginal myomectomy is the treatment of choice. When the tumor is so situated as to make a satisfactory vaginal myomectomy impossible, the neoplasm should be removed from above. Irradiation, either by X-ray or radium, is not a satisfactory means of treatment of cervical fibromyomata.

CHAPTER II

CARCINOMA AND OTHER MALIGNANT TUMORS OF THE CERVIX

CARCINOMA OF THE CERVIX

ETIOLOGY.—The *cause* of cancer is unknown. Three predisposing *factors* are recognized, however, namely, age, chronic irritation, and heredity.

Age.—The greatest number of cases of carcinoma of the cervix occur at or a few years before the menopause. The disease is most frequent between the ages of thirty-five and fifty-five years. Thus, on an average, carcinoma of the cervix develops about five to eight years earlier than that of the fundus. About 5 per cent of cases occur in patients thirty years of age or younger, and a like proportion in patients over sixty. A case has been recorded in an infant six months of age by Findley.[1] Rosenstern [2] records the history of a case of carcinosarcoma in a child of two years, and Engelhorn [3] and Glockner [4] record cases in extremely young subjects.

Carcinoma of the cervix originates in the cervix, and is a separate tumor distinct from that of the fundus. The symptoms, diagnosis, prognosis, and

treatment differ in these two varieties of cancer. Occasionally a tumor may spring from the mucosa at the cervico-uterine junction or, because of the advanced stage of the lesion, the point of origin may be difficult to determine, As a rule, however, no confusion should exist. A histological examination will generally clear up this point in doubtful cases.

It is said that this disease develops somewhat earlier in negroes than in white persons, but Green-Armytage has observed many advanced cases in young women in India. It occurs somewhat earlier in races of early sexual maturity, and later in the inhabitants of Northern countries.

Regardless of race and climate, carcinoma occurs earlier in women with early menopause. Many cases of early cancer have been reported following surgically or artificially induced menopause. Cervical carcinoma apparently occurs somewhat later in the nulliparous than in those who have born children.

Chronic Irritation.—Child bearing leads to lacerations of the cervix, and lacerations predispose to infection. It is the irritation incident to the latter which is probably the important etiologic factor in the development of cancer, rather than the lacerations per se.

The portio vaginalis is covered by stratified squamous epithelium. This may be considered as

FIG. 2.—*Normal Cervix.* Showing the squamous epithelium covering the portio and being replaced abruptly at the external os by the high columnar epithelium of the cervical canal.

a modified derma, and shows considerable resistance toward trauma and infection. This epidermoid protective tissue extends over the outer surface of the cervix and to the external os, and occasionally farther upward in the canal. The cervical canal is lined by columnar epithelium, a delicate and easily traumatized type of tissue, which exhibits relatively low resistance against infection. The cervical canal is normally sterile and alkaline in reaction. The vagina is acid in reaction, and is frequently contaminated.

Lacerations of the cervix lead to exposure of its mucosa to infection and trauma, with resulting cervicitis.

Cervicitis is one of the most frequent forms of infection in women, and is notorious for its chronicity and resistance to treatment. In practically all women who have born children, and in whom a cervical repair has not been performed, some degree of cervicitis is present. Chronic cervicitis is also common in the nulliparæ. The clinical association of long standing chronic irritation and carcinoma is too well known to need comment. Virchow noted the relationship of chronic irritation and cancer. Billroth stated that, "without chronic inflammation cancer does not exist."

Pipe-smokers' cancer, scrotal cancer of chimney-sweeps, buccal cancer associated with rough teeth,

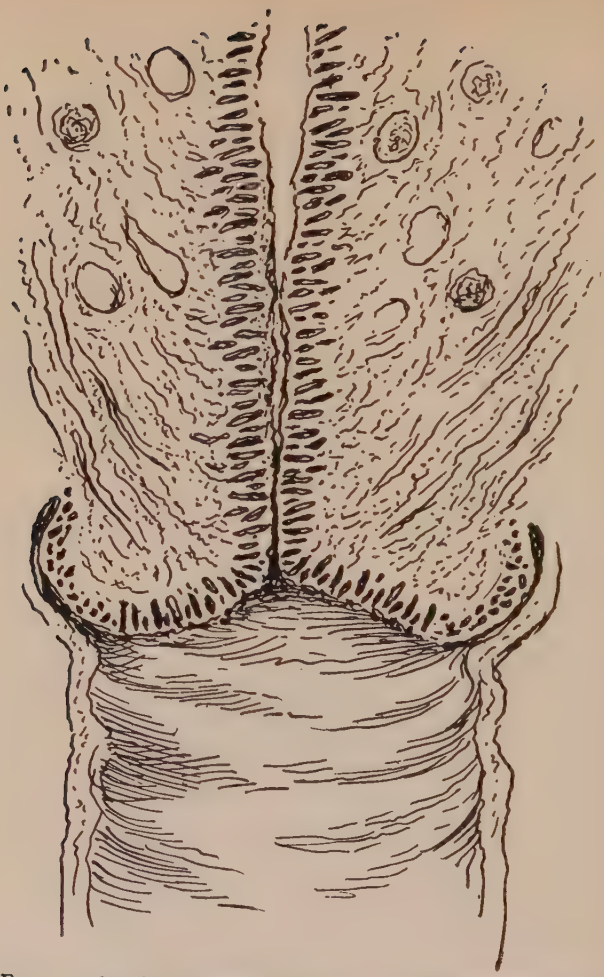

FIG. 3.—*Cervix showing the results of laceration and eversion.* The mucosa which should normally be protected in the canal is exposed to the trauma and bacterial invasion of the vagina, and as a result becomes hypertrophied and infected, constituting a chronic irritation which is a predisposing factor to the development of carcinoma.

X-ray cancers, mouth cancer of betel-nut chewers in the East, mule-spinners' cancer, "Kangri cancer" of the inhabitants of northeastern India from the use of the warming boxes, and cancer of the esophagus in Chinese from eating hot rice, are all well recognized. Cancers developing upon chronic ulcers, such as gastric or intestinal-tract ulcers in general, and in the liver, kidney, breast, and many other localities, have been observed.

In 1914, Febiger produced cancer in the stomach of rats by feeding them cockroaches infected with the organism, *Spiroptera neoplastica.* A few years later the Japanese investigators, Yamajiwa and Itchikawa, produced cancer in the ears of rabbits by repeated applications of coal tar. The results of the latter experiments have been verified by many investigators. To produce experimental carcinoma, the irritation must be continued over a long period. It is of interest to note that laboratory carcinoma does not develop uniformly in all animals, even when they are of the same species and similarly treated. Ordinarily, only a certain proportion of the animals develop cancer after treatment with coal tar. This proportion varies with different strains of the same breed. Cancer-resistant and cancer-susceptible strains of animals have been developed. The coal-tar irritants themselves vary in cancer-producing properties, some appearing

harmless, while others produce tumors in mice in seventeen weeks in all cases (see International Conference on Cancer, 1928).

The period of "incubation" of cancer is unknown, but in a few instances the disease has become manifest in laboratory animals long after the application of the irritant has ceased.

Carcinoma of the cervix is essentially a disease of the multiparæ, less than 10 per cent of cases occurring in the nulliparæ. Careful study of any series of cases occurring in the nulliparæ will show that some of them have been submitted to various splitting or dilatation operations, often for sterility or dysmenorrhea, while a few may have reasons for concealing a past pregnancy. After these cases have been considered, however, a number of cases still remain in which the cervix has never been submitted to trauma. The part played by gonorrhea and non-specific infection of the cervix in the development of carcinoma in nulliparæ is difficult to determine, but is, no doubt, of importance in a small proportion of cases. Cervical stenosis often results in retarded drainage of the cervical canal and a form of non-specific cervicitis, and this is also a probable etiological factor in certain cases of carcinoma in the nulliparous.

Many investigators have studied the effects of cervical repair. Graves found that, among 538 cases

of carcinoma of the cervix, only 12, or about 2 per cent, had had a cervical repair. In 2 of these 12 cases the carcinoma was present at the time of the repair, and they can, therefore, be excluded. Doubtless, in some of the remaining cases the repair was imperfectly performed, or a satisfactory result not secured, for some other reason. Among 4,815 cases of cervical repair studied by Graves he was able to find but 7 that later developed carcinoma. In 3 of these (including the 2 mentioned above) the pathologist had overlooked a cancer which was present at the time of the plastic operation. In 2 other cases it could be shown that the operation had been injudiciously performed and had resulted in an extremely obstructing stenosis of the upper vagina and cervix, conditions which probably play an important part in the production of genital carcinoma. Graves' summary shows that in nearly 5,000 cases of cervical repair, only 4 developed cancer later on, and that in 2 of these the operative result was not satisfactory. In this series the incident of carcinoma developing in a cervix subjected to repair was 2–4000. Numerous more or less similar statistics could be quoted, but these are sufficient to show the etiologic relationship between long-continued chronic irritation and the development of carcinoma, as well as the prophylactic value of properly

performed plastic operations upon the lacerated cervix.

Heredity.—Cancer is so frequent that practically every family history reveals sufferers from this disease. It is probable that in the human race heredity is not often an important practical factor and, therefore, a case or two of the disease in a person's family should not cause any serious concern. Among animals, a different state of affairs exists. Maude Slye has definitely shown that certain strains of animals exhibit a marked predisposition to the development of cancer, while other strains rarely develop the disease. Slye's work has extended over the last eighteen years. The inherited susceptibility or immunity against cancer follows the Mendelian law as closely as does albinism and coloration. Slye's work and that of others definitely show the inherited tendency toward or resistance against cancer, which exists in mice. Experimental work has also shown that the resistance of normally immune mice can be destroyed by the prolonged application of irritants. In the pure strains of cancer-susceptible mice, all die of spontaneously developed carcinoma after reaching a certain age. In these strains the artificial production of cancer is more easily and quickly accomplished.

If experimental evidence regarding mouse cancer is applicable to the human race, then it is easy to

explain the development of cancer in some women with slight lacerations of the cervix, and the non-development in others with lacerations of greater extent and longer standing. It would appear that there can be little doubt that there is such a thing as cancer-susceptibility and cancer-resistance, and that occasionally men and women are born who are almost certain to develop the disease, provided they live to reach the cancer age. This fact is more or less borne out by the existence of a few so-called cancer families which have been observed from time to time. As emphasized by Carter Wood, little is known regarding the actual degree of susceptibility and resistance to cancer which is present in the human race.

Cancer has been attributed to civilization, various diets, climates and geographical conditions, certain soils, contagious cancer-houses, etc. Needless to say, none of these theories have been proved, although the disease does appear more commonly among civilized than savage races. It has been claimed that cervical carcinoma is relatively infrequent among Jewesses.

The physician is powerless against the influence of age upon the development of cancer and, indeed, has done much to prolong the average life of the individual, thus allowing a greater number of persons to reach the cancer age.

So little is actually known regarding the influence of heredity among humans that eugenics seems to offer little prospect of diminishing the frequency of the disease, and as the disease does not usually develop until after the child-bearing age, an added difficulty to this form of prophylaxis is present. Much can, however, be done to eradicate chronic irritation, and this is considered in detail under the heading "prophylaxis."

Frequency.—Carcinoma of the cervix is the most frequent malignant tumor encountered in gynecological practice. Ninety-three per cent of all genital carcinomata are uterine, and 81 per cent of all uterine tumors are cervical in location. In our own laboratory of gynecology, carcinoma of the cervix constitutes nearly 4.9 per cent of the total number of pathological specimens. Scherechewsky states that the death rate from carcinoma of the female genitalia rose enormously during the period 1900–1920, and in a recent publication the American Society for the Control of Cancer emphasized the fact that cancer is rapidly gaining in this country. Whether this is an actual increase or is due to more accurate methods of diagnosis, more careful statistics, and to the fact that the average age of the population is increasing (resulting in a greater proportion of persons reaching the cancer age), or other causes, is a controversial matter. It is, how-

ever, certain that cancer is one of the most important causes of death in persons over forty years of age. McConnel has prepared the following statistics, showing the distribution of the tumors in 1,000 cancer deaths of women:

Uterus	276.2
Stomach	244.7
Breast	157.8
Liver	125.9
Abdomen	76.9
Rectum	35.5

Carcinoma of the cervix is about five times as frequent as of the fundus. This can be accounted for by the fact that chronic cervicitis is common, whereas chronic corporeal endometritis is rather infrequent and, if we exclude the tuberculous variety, quite rare.

Pathology.—Carcinoma may originate in any part of the cervical epithelium. The most frequent site is at the external os. Next in frequency come the portio and the surface epithelium of the cervical canal, and last, the glandular epithelium.

The exact point of origin is generally difficult to determine, as the cancer rarely is observed in its early stage. It may be inverting or everting, and occurs in three clinical varieties: (a) the ulcerative, (b) the papillary, proliferative, vegetative, or cauliflower, and (c) the interstitial or intramural. All the varieties become ulcerative in the late stage.

Frequency of Different Varieties.—As has already been stated, the very early carcinomata are rarely observed. The earliest stage is a hard induration without loss of surface epithelium or, in the papillary variety, a minute area extending above the surface composed of cauliflower-like excres-

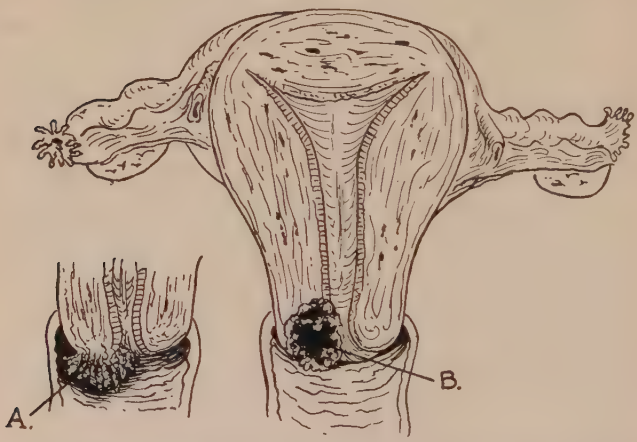

FIG. 4.—*Carcinoma of the Cervix.* A—Represents a papillary carcinoma of the cervix. B—Shows the ulcerative type.

cence. In the former, the nodule soon breaks down and develops the typical appearance of the ulcerative variety. Cullen describes three stages: (1) induration without loss of tissue, (2) disintegration, and (3) excavation. The well-developed ulcer has a hard base, with irregular and sometimes undermined edges. The surface is often covered with

necrotic material, which presents a blackish, greenish, or brownish appearance and produces a slippery feel to the palpating fingers. If the necrotic material does not cover the entire lesions, or if it is removed, the surface of the ulcer can be seen to be pinkish or reddish, composed of opaque, homogeneous, semitranslucent, friable tissues which tend to break down and bleed easily upon slight trauma. The edges are usually slightly raised and the neighboring tissue is firmer than normal.

The papillary type presents an excrescence, the appearance of which justifies the term "cauliflower variety." The papillæ present a somewhat rounded surface and are closely aggregated, forming a pinkish or whitish tumor, which is extremely friable and vascular. It is usually bathed in discharge, and is more or less necrotic upon the surface. In the later stage macroscopic ulceration is often present. The papillary carcinoma is usually sessile, but may be pedunculated. Its friable, vascular, cauliflower-like appearance is characteristic. Carcinomata which have their origin within the canal are more difficult of detection in the early stage. The most common site is in the lower half of the canal, where they often extend downward, eroding the external os, and therefore are often first observed as a deep ulcer with, in the earlier stages, a small opening at the external os.

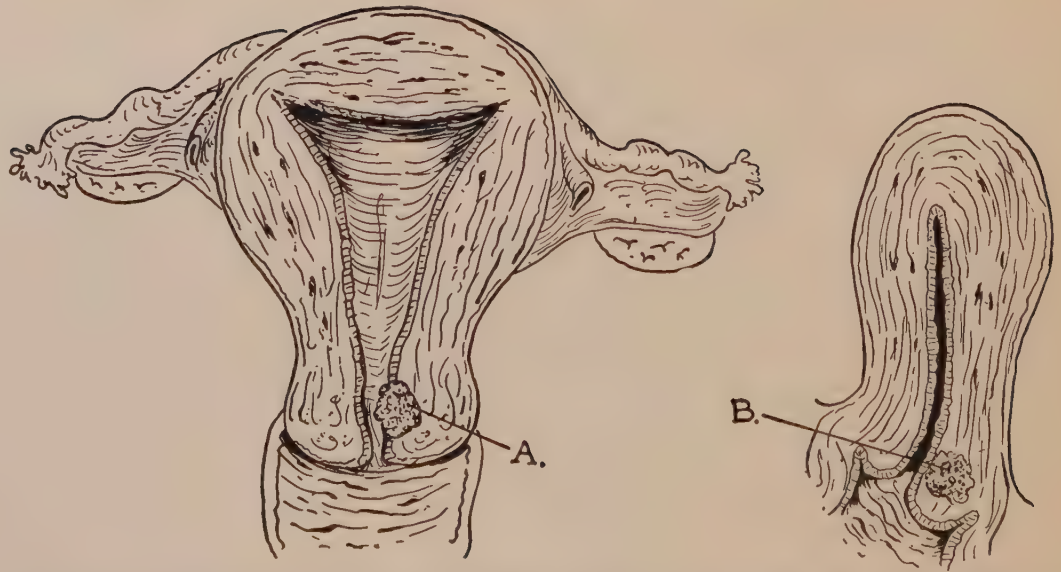

FIG. 5.—*Carcinoma of the Cervix.* A—Carcinoma originating in the canal. B—A rather infrequent form originating in the depths of a cervical gland. Carcinomata in both these localities are more difficult to recognize than when originating upon the portio.

The interstitial or intramural variety is the least common, and generally reaches a most advanced stage before producing symptoms. The tumors of this type originate in the epithelium of a cervical gland, and at first appear as small nodules which finally erode into the canal or upon the portio. Except for the presence of a nodule—which in its early stages may readily be mistaken for a Nabothian cyst—this variety produces no symptoms until the disease has eaten its way into the canal or to the surface of the portio.

The appearance of cervical carcinoma is generally characteristic in the advanced cases, but by no means typical in the really early lesions. Those tumors which originate in the portio are especially likely to involve the vagina during the course of their growth, and a vesicovaginal or somewhat less frequently recto-vaginal fistula may result in the end-stages of the disease. Those carcinomata which develop within the canal sometimes spare the outer surface of the portio. They often extend upward, but macroscopic invasion above the internal os is not common, although lymphatic extension past this point occurs in the terminal stage of the disease in about 40 per cent of cases. All varieties tend to extend laterally at a relatively early stage of the disease. The papillary form remains localized the longest, and is most amenable to treatment.

The lymphatics of the cervix run from the mucosa and muscularis toward the periphery, where they unite to form two or three larger vessels. These pass outward, in the base of the broad ligament, in rather close association to the uterine artery. At the pelvic wall they turn upward, to reach the glands situated at the bifurcation of the common iliac. This is the common route for metastasis, and the glands are usually involved even in a moderately early stage. Cervical carcinoma metastasizes somewhat earlier than that of the fundus. Even in advanced cases the disease usually shows a tendency to remain localized to the pelvis. The poor results of the treatment can largely be accounted for the by close anatomic relationship of the cervix to the bladder, ureter, and rectum.

Metastasis is dependent upon many factors: the advancement of the tumor, its duration, the relationship to lymphatics and blood-vessels, the diameter of the blood-vessels and lymphatics, the size of the tumor cells, the amount of stroma within the tumor, its consistency and friability, trauma, and probably other factors of which little is known. Cervical carcinoma occurring in the young, or in association with pregnancy, apparently metastasizes more rapidly than in the aged. Post-mortem observations show a varying percentage of metastatis;

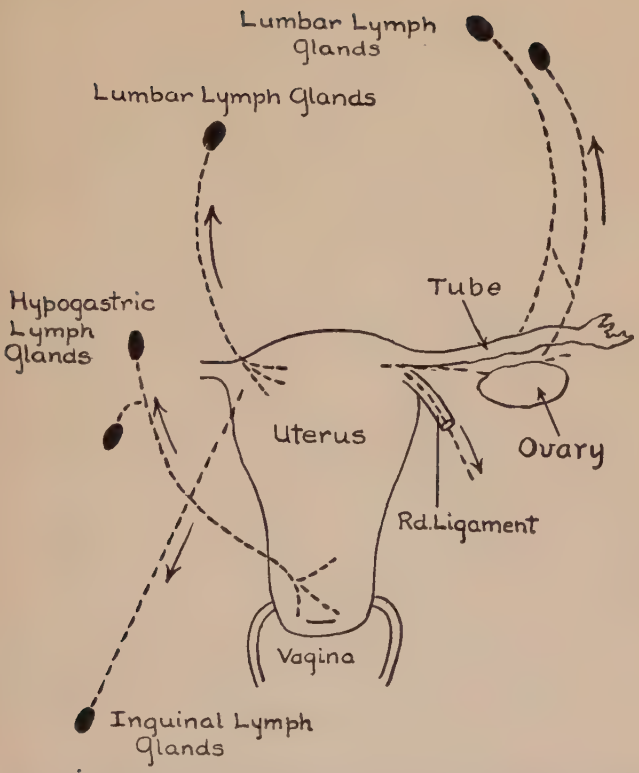

FIG. 6.—Diagram showing the course of lymphatic drainage from the uterus and the common routes of metastasis from fundal and cervical carcinoma.

thus, Kroemer [5] found the lymph-nodes free in 66 per cent of fatal cases, Kundrat (quoted by Ewing) in 160 cases found the parametrium and its nodes invaded early in 55 per cent, Lamaris and Kermauner found extension in 57.5 per cent, Baish in 36 per cent, Shauta in 64 per cent. Baish believes that the regional lymph-nodes are invaded in one third of the early, or so-called operable, cases. When the parametrium is macroscopically free, in 5 to 10 per cent of cases the nodes are involved, while with macroscopic involvement of the parametrium, the nodes are invaded in 50 per cent of the cases. The invasion may be by continuous permeation, or sound tissue may separate the nodes from the cervix.[6] Only histologic examinations can determine the question of metastasis. Distant metastasis occasionally occurs. The writer has observed metastases in the skull, tibia, and other remote areas.

For many years pathologists have, with more or less success, attempted to correlate the histologic pictures produced by malignant neoplasms with the clinical malignancy of the tumor. Bröder's important findings in relation to carcinoma of the lip, and Greenough's work upon carcinoma of the breast have demonstrated how valuable such a grading may be. Martzloff, Schmitz, Healy and Cutler,[7] Norris and Kimbrough, and others have contrib-

uted papers relating to the relative malignancy of cervical carcinoma. In some parts of the body the malignancy of carcinoma shows considerable variation, and in such areas histologic grading is relatively easy, while in other localities—*e.g.*, the cervix—all cancers are highly malignant and their grading more difficult and less definite.

The advent of radium irradiation in the treatment of cervical carcinoma has stimulated this work, as it has been found that, as a rule, malignancy and radiosensibility are directly proportional. In 1905 Bergonie and Tribondeau,[8] after repeated studies, were led to make the following generalized statement, which has become known as the law of Bergonie and Tribondeau: "Immature cells and cells in an active state of division are more sensitive to irradiation than are those cells which have acquired their fixed adult morphologic and physiologic characters." This law has stood the test of time and, with few exceptions, holds good throughout the entire field of radiology.

The possibility of successful grading of cervical carcinoma is not uniformly accepted. Some pathologists believe that beyond the previously mentioned divisions of epidermoid or squamous-celled, and adenocarcinoma or glandular, no further progress can be made by cellular pathology along this line.

They base this upon the assumption that different portions of a tumor present different histologic appearances. The author is not in accord with this view. It is true that, as previously stated, all cervical cancers are of a relatively high malignancy and their grading is therefore less sharply defined than that of tumors with greater range of variation in this respect. The importance of this subject is apparent. Bröder's work is based chiefly upon the relative number of cells undergoing division in a given area, a certain number of fields being counted and averaged. His results have been amply supported by study of groups of cases which have been carefully followed up. Martzloff,[9] working with 387 cases of cervical carcinoma which were treated by operation, has shown that the end-result depends upon the type of cell predominant in the tissue. He distinguishes between three types of carcinomata—namely, the spinal-cell, the transitional-cell, and the spindle-cell carcinoma. The adenocarcinoma stands between the transitional-cell and spindle-cell types in malignancy. Martzloff found involvement of one or both broad ligaments within six months after the onset of symptoms, in every case of all groups except the spinal-cell. He presents the following table, showing the percentage of "five-year cures" for the different types of epidermoid cancer:

	Johns Hopkins Bull. (Martzloff) Per cent	*Mayo Clinic* (Bröder's personal communication) Per cent
Spinal-cell Grade 2 of Bröder's	47.00	53.33
Transitional-cell Grade 3 of Bröder's	24.2	21.5
Fat spindle-cell Grade 4 of Bröder's	9.5	9.52

Our own work in the Gynecological Division of the Hospital of the University of Pennsylvania has chiefly been concerned with cases submitted for irradiation, and in general verifies the above conclusions. Unripe varieties of cervical cancer were followed by local healing in 76 per cent of cases. Mid-ripe varieties of cervical cancer were followed by local healing in 51 per cent of cases. Ripe varieties of cervical cancer were followed by local healing in 40 per cent of cases. Our results based upon five-year cases were less striking, there being little difference in the number of cures of the different varieties at the end of five years. This may probably be explained by the fact that the unripe types are of greater malignancy, grow more rapidly, and give earlier metastases, thus balancing their greater radiosusceptibility. Schmitz, Hueper, and Arnold [10] in a large measure confirm this. They have arranged a numerical scale of the various factors influencing the prognosis, the sum representing the histological

malignancy index. They found that the relation of the cell type to the malignancy index is definite. The unripe type was always associated with a high malignancy index. Lahm and Roussy [11] found that the histologic examination was of definite prognostic value. Fluhmann [12] is of a similar opinion.

The subject of malignancy grading and radiosusceptibility has not yet been worked out in its entirety, some points still being much disputed. The most careful work, however, seems to show that the epidermoid cervical tumors may be divided into at least three groups, and that these differ quite markedly in malignancy, rapidity of growth, and stage in which metastasis occurs. As all cancers of the cervix are highly malignant, the differences are here less obvious than in cancers of some other areas. Tumors representing intermediate grades are also found. On the whole, however, it seems proven that the histologic examination by an experienced pathologist is of distinct value in determining the relative malignancy of a given tumor, and that it is of prognostic importance when considered together with the other factors—advancement of growth, etc. Epidermoid carcinomata are of the same histologic type throughout their entire bulk, although local variations may occur as a result of alterations in the blood supply, degeneration, or pressure. These produce different histologic pic-

tures, but do not alter the type to which the tumor belongs, any more than over-ripeness, differences in size and shape, etc., would change a pear into some other kind of fruit. This latter fact bears upon the value of biopsy, as it has been claimed that, unless the entire tumor is examined, it is impossible to determine its type, an opinion which seems to have been disproved by the work of many competent observers.

To recapitulate, cervical carcinoma may be divided into two main histological varieties—the epidermoid and the adenomatous or glandular. The former may be further divided into three or more subdivisions, according to predominating type of cell. These may be designated ripe, mid-ripe, and unripe (Fluhmann); or spinal-celled, transitional-celled, and spindle-celled (Martzloff). The adenocarcinoma is composed of a moderately adult type of cell, and is an intermediate form between the ripe and mid-ripe varieties. Other things being equal, the more embryonal tumors are more highly malignant and more susceptible to the influence of irradiation—either by radium or X-ray.

Carcinomata composed of both glandular and squamous epitheliums are occasionally encountered and are designated adeno-acanthomata. Such tumors are generally the result of a metaplasia of cylindrical epithelium into the squamous variety. It is

possible that some adeno-acanthomata are of multicentric origin, but this is probably of rare occurrence. Metaplasias of the cylindrical epithelium of the cervix are frequent in benign conditions, and there is every reason to believe that a similar process may take place in carcinoma. Adeno-acanthomata present the same clinical characteristics as are found in the more common forms of carcinoma.

Symptoms.—In 90 per cent of patients, the disease occurs in multiparæ and usually at about the menopause or a few years earlier. Carcinoma occasionally occurs in nulliparæ. Long-standing chronic cervicitis is undoubtedly a predisposing factor. Carcinoma is relatively rare before thirty and after sixty years of age. The important symptoms are hemorrhage and discharge.

Hemorrhage is usually metrorrhagic in type, it follows trauma, as a rule, but also occurs without demonstrable insult, and is rather rapidly progressive in character. The character of the hemorrhage can be readily explained by a study of the histology of the lesion. Cervical carcinomata are friable, vascular neoplasms, hence, a slight hemorrhage occurs, often designated by the laity as spotting, when small portions of the surface are broken off as a result of trauma or disintegration due to necrosis. The tumor-cells sometimes erode into a large blood-vessel, causing a severe hemorrhage. Occasionally

this occurs early in the disease, but, as a general rule, the bleeding is slight in the early stages. As time goes on, however, the hemorrhages become more frequent and more profuse, and the intervals between the periods of bleeding shorter. The blood is bright red. Toward the end-stage of the disease, bleeding is often almost constant. A discharge of bloody watery fluid is present most of the time, with occasional periods of severe hemorrhage. There is, however, a considerable variation in the amount of bleeding in the different cases. Anemia and its accompanying symptoms finally develop. It is probable that cervical carcinoma in no way influences menstruation. Occasionally, an apparent prolongation of the period may occur, as the result of a hemorrhage taking place just before or after the normal menstruation. True, menorrhagia may result from inflammatory or congestive lesions of the ovary or, occasionally, from other forms of ovarian disease, or even actual metastasis.

Hemorrhage is the most important symptom in cancer of the cervix. It is probable that discharge antedates hemorrhage in the majority of cases. Carcinoma rarely develops in the normal cervix, however, and lacerations, eversion, and cervicitis usually precede the disease. As a result of these lesions, a more or less marked leucorrhea has usually been present for some time, often for years, prior to the

development of carcinoma. Hence, the discharge incident to the carcinoma is but an alteration in amount or character of a symptom which has been present for a prolonged period, and is less likely to attract the notice of the patient than is the bleeding, which in itself is an unmistakable and noticeable symptom. The discharge resulting from carcinoma is at first small in amount, thin, watery, irritating, and slightly malodorous. It soon becomes thick, from admixture of the cervical mucus. Due to necrosis of the tumor, it becomes offensive in odor, brownish in color, and often blood-tinged. By the time the discharge has become pronounced, irregular hemorrhages have usually been present for some time. As a diagnostic symptom, hemorrhage is nine or ten times as significant as discharge.

Cervical carcinoma is far more insidious than many text-books would indicate. Despite the fact that its presence or absence usually can be easily proven by biopsy, it is rarely detected in an early stage. The truth of the matter is that, despite the fact that the cervix is easily accessible to both sight and touch, the subjective symptoms in the early stage of cervical carcinoma are so vague—indeed, even absent in some instances—that patients are prone to overlook them. The discharge is often ignored by the patient, for the reason already mentioned, and the hemorrhage is too often attributed

to an irregularity of menstruation incident to the approach of the menopause, or to a recurrence of menstruation after the menopause. Furthermore, during the early stage, the interstitial variety produces no symptom except the presence of a small nodule which, if discovered, may readily be mistaken for a benign lesion. Carcinomata which originate within the canal may not be detectable except after dilatation of the external os. Many complicating factors may be present, making a positive diagnosis difficult even when the growth springs from the portio. Pregnancy, some types of laceration, and the presence of obstructing benign lesions such as myomata, all mitigate against the recognition of carcinoma in its early stage. At best, the early symptoms of cervical carcinoma are mild and painless and for these reasons the disease is rarely seen during this stage. In a series of 361 cases, observed in the Radiological Department of the Philadelphia General Hospital, the patients had allowed a period of (on an average) four months to elapse after onset of symptoms before seeking medical advice. This means that the tumors had probably been present for at least six months before a physician had an opportunity of making a diagnosis. Four months from the onset of symptoms is, as a rule, sufficient time for the tumor to advance to the so-called inoperable stage (Stage II or III). It is obviously

unjust to blame the general practitioner for the advanced stage in which many cases are first seen by the consultant. Cachexia, pain, loss of weight, etc., are generally indications of an advanced and hopeless condition. Hemorrhage and discharge are the only subjective symptoms of value in the early stage of the disease and, with risk of repetition, it may be stated that even these are usually mild, painless, and far from pathognomonic. Spotting is perhaps the most suggestive single symptom, especially when following slight trauma, and should never be passed without a thorough investigation to determine its cause.

Diagnosis.—The importance of early diagnosis of cancer can hardly be overestimated. This has been stressed repeatedly by all who have studied the subject. Early recognition of the disease is the most important prognostic factor, and has a more direct bearing upon the ultimate outcome than any other one point. Our own results have shown that 75 per cent of early cases survive for five years or more, and that this percentage diminishes with the advancement of the disease until, in the late stages, the proportion of final salvage is practically *nil.* There would be no necessity to dwell upon this well-known fact, were it not the disheartening experience of every consultant still to encounter cases which have been unrecognized for prolonged pe-

riods. Fortunately, these instances are each year becoming less frequent. Although the subjective symptoms of early cervical carcinoma are usually mild and far from characteristic, they are usually sufficiently suggestive to call for a thorough investigation. It is obvious that this cannot be done unless the patient consults her medical attendant, and it is on this point that the dissemination of knowledge to the laity by various medical and lay organizations is especially valuable.

The average case of cancer developing in the cervix should be recognized in its early stage. The cervix is accessible to sight and touch and, in case of doubt, biopsy is easily performed. In spite of this, the lamentable fact remains that not more than 10 per cent of cases come under observation in this stage. Of 253 patients with cervical cancer, who applied to the Gynecological Division of the University Hospital for treatment, 86.3 per cent were positively diagnosed by the consultant; in an additional 11.4 per cent the disease was suspected, and the diagnosis verified by histologic examination; and in only 2.3 per cent of cases was malignancy not suspected.[13] This is a striking contrast to what occurs in fundal carcinoma. In a series of 101 carcinomata of the body of the uterus, 19.8 per cent were of the unsuspected variety, while only 56.4 per cent were positively recognized by clinical signs

alone. In considering the above-mentioned figures, it should be remembered that these cases were studied by specialists and that the proportion of correct clinical diagnosis, therefore, is probably considerably higher than they would have been if the same cases had been observed in general practice. Furthermore, the majority of these cases were advanced.

There are a few conditions which so closely simulate carcinoma that a correct diagnosis is almost impossible from clinical signs alone. Tuberculosis of the cervix produces a lesion that closely resembles carcinoma and, because of the rarity of the former condition, is usually diagnosed as the latter. In a series of 128 cases of cervical tuberculosis collected from the literature [14] over 88 per cent were diagnosed clinically as malignant. Syphilis may also produce a lesion that strongly suggests carcinoma. Extensive laceration with eversion is often suggestive of malignancy, particularly when complicated by pregnancy. Adenomyoma of the rectovaginal septum may produce a condition that closely simulates carcinoma. Degenerated benign cervical tumors not infrequently suggest carcinoma. The microscope is the court of ultimate resort in all doubtful cases. A competent pathologist can with certainty recognize carcinoma in every case. One of the possible sources of error in biopsy is that car-

cinoma may be present, but the tissue presented to the pathologist may be free from the disease. Fortunately this is rather improbable, but in the early cases, and it should always be borne in mind that these are the ones which offer the greatest diagnostic difficulties and are the most important to recognize, it is not always easy to find the proper point for a biopsy. This operation should be performed with a sharp knife, a piece of tissue not less than 1.5 x 1 x 0.5 cm. being removed. This should include the edge of the suspected lesion and a small margin of adjacent tissue. In cases of doubt two pieces of tissue may be excised. The tissue should immediately be placed in 4-per-cent formalin solution, or whatever fixing agent is selected. The wound may be seared with the cautery knife, and a catgut stitch inserted. No anesthetic is necessary. It has been claimed that the trauma incident to biopsy may be a factor in the dissemination of the tumor. While this is theoretically true, the risk is minimum and does not compare with the danger of treating a suspicious lesion palliatively. Furthermore, the employment of a sharp knife followed by the use of the cautery minimizes hazard which may be present. Biopsy should be employed at once in all suspicious cases, unless a high trachelectomy is indicated for other reasons.

The following table presents the points to be con-

sidered in the differential diagnosis between cervical carcinoma and lesions which are prone to cause confusion:

CARCINOMA	TUBERCULOSIS	LACERATIONS
Age 30–60, average 45	Any age	Puberty or later
Past history		
90 per cent multiparæ	Parity incidental	Childbirth
Previous cervicitis	Suggestion of tuberculosis elsewhere in body—susceptibility to colds, bone, or joint lesions, etc.—often quiescent and difficult to demonstrate	
Onset		
Spotting or discharge	Cervical symptoms, preceded by pelvic or general peritonitis (a descending infection)	Leucorrhea dating from childbirth
Duration		
Evolution of symptoms rapid	Evolution of symptoms slow, often covering several years	The only symptom is leucorrhea. This is extremely chronic
No adnexitis	Adnexitis is the rule and is usually bilateral	No adnexitis
Physical examination		
No evidence of t.b.	A primary focus is present, in lungs or elsewhere, often quiescent and difficult to demonstrate	No evidence of t.b.
Abdominal examination		
Signs of previous parity	Parity incidental, often absent	Signs of previous parity
Tenderness absent	Tenderness over adnexa	No tenderness

Pelvic examination		
Signs of parity	Parity incidental	Signs of parity
Cervix		
Ulcer, papilloma, or nodule—sometimes concealed in canal	Ulcer, papilloma, or nodule	A laceration with eversion—no actual macroscopic ulcer
Mucosa adjacent to lesion is normal or slightly reddened	Mucosa adjacent to lesion is often reddened, and often contains macroscopic tubercles	Mucosa adjacent to lesion is normal—no tubercles
Bleeds readily on trauma	Bleeds less readily on trauma	Does not bleed, or bleeds less readily on trauma
Friable	Friable	Firm
Base and edges of ulcer hard	Base and edges of ulcer less firm, often containing macroscopic tubercles	Base and edges of lesion less firm, often velvety
Except in early Stage I cases, surface blackish green, necrotic	Less often necrotic	Reddish, pink
Smears show pyogenic organisms, often streptococci	Smears may show t.b. but the smegma bacillus must be excluded	Smears may show various pathogenic micro-organisms, but no t.b.

As will be seen, the differentiation between carcinoma and tuberculosis is generally difficult, and may be impossible without a histologic examination. The age of the patient, duration of the disease, the history suggestive of a primary lesion, the presence of macroscopic tubercles in or adjacent to the lesion, and an accompanying or preceding adnexitis are all

suggestive and important diagnostic points. Carcinoma is 200 to 400 times as frequent as tuberculosis and, owing to this fact, mistaking the latter for the former is much more likely than the reverse. Syphilitic lesions which are likely to be confused with cervical carcinoma are extremely rare. Syphilis is a common disease, and little weight should be attached to the fact that the Wassermann reaction is positive. In carcinoma of the external genitalia, it is common to find that the patients have been treated for a prolonged period for syphilis, merely because of a positive Wassermann reaction. Fortunately, this is less frequent in cervical lesions.

The character of the lesion, the history, duration, and lesser tendency toward bleeding, usually clearly distinguish lacerations from carcinoma, but some cases may be observed in which a diagnosis is impossible without laboratory aid. When lacerations are associated with pregnancy they take on a greater similarity to carcinoma. Eversions become extremely vascular, bleed more readily as a result of trauma, and, at least superficially, are often suggestive of carcinoma. The recognition of carcinoma by clinical methods is generally easy by the time the patients seek medical advice. It is the early cases or those which, for some reason, are atypical which are likely to cause confusion. In all doubtful cases, biopsy or trachelectomy should be resorted to with-

out loss of time. Biopsy is an easy and safe operation, does not require an anesthetic and, if the tissue is taken from the proper site and is submitted to a competent pathologist, offers a quick and certain means of establishing the diagnosis.

Prognosis.—Unripe tumors, small-celled tumors, and those which originate within the canal and are ulcerative are the most malignant. In general, cervical carcinomata grow more rapidly and produce metastasis earlier when present in young patients. Pregnancy exerts an unfavorable influence on the prognosis. Of the three clinical varieties—the ulcerative, papillary, and intramural—the papillary is decidedly the least malignant. The intramural variety and the neoplasms originating within the canal tend to be more silent, and generally present greater diagnostic difficulties in their early stages, hence, they are usually more advanced before recognition is possible.

Pregnancy not only results in rapid growth of the tumor, but as a result of the increased vascularity incident to gestation, masks the early carcinomata. Thus, these are rarely recognized, and are often mistaken for eversions, resulting in a delay in diagnosis. The hemorrhage in these cases may be attributed to a complication of pregnancy, such as threatened abortion, placenta prævia, or even premature separation of the placenta. Cullen [15]

and Lubarsch [16] attribute special infiltrative powers to the tumor composed of small cells, a view which is in accord with the small size of the cells in many highly anaplastic growths. Other things being equal, it is logical to believe that neoplasms composed of small cells result in earlier and more distant metastasis.

All cervical carcinomata are highly malignant and, on account of the anatomic relations of the cervix, difficult of complete eradication by any known means. Therefore, the stage of the lesion at which the diagnosis is made is the most important prognostic factor in every case, regardless of form of treatment.

Classification of Advancement.—For purpose of comparing the mortality and end-results of cervical cancer, some uniform method of classification of the different stages of the disease is of utmost importance. Various classifications have been suggested. One of the most satisfactory is that of Schmitz,[17] which is as follows: Stage I—cases in which the cancer is apparently localized in the cervix. Stage II—the so-called border-line cases, in which it is questionable whether the cancer has extended beyond the cervix. Stage III—the so-called inoperable group, in which the disease has extended beyond the cervix. Stage IV—advanced cases, with large necrotic craters, cachexia, and the

"frozen pelvis." Stage V—recurrences. The last group may be further subdivided into early, moderately advanced, and advanced. This is the grouping which has been adopted in the Hospital of the University of Pennsylvania, the Radiological Department of the Philadelphia General Hospital, and by Ward in the Women's Hospital in New York, and is practically that employed by Greenough [18] in his report to the American College of Surgeons. This classification has the advantage of simplicity, is applicable before operation, and is almost self-explanatory. In the Stage I carcinomata the lesion is rarely more than 1.5 or, at the most, 2 cm. in its greatest diameter. It is localized to the cervix. The broad ligaments are normal. The cervix and body of the uterus retain their normal mobility. There are no enlarged glands or other demonstrable evidence of extra-cervical extension. In Stage II, or border-line, cases, the lesion is generally 1.5 cm. or more in its greatest diameter. There may be slight thickening or induration of the base of one of the broad ligaments, and slight fixation of the cervix or lessening in its normal range of mobility. There is no positive evidence of extension beyond the cervix. Stage III—The palpable or visible lesion is generally 2 or more cm. in diameter. There is definite evidence of extension beyond the confines of the cervix, as evidenced by palpable extension to one

or both broad ligaments, bladder, rectum, or vagina. Infiltration of the base of the broad ligament is the most common palpable evidence of early extension beyond the cervix, whereas, in the ulcerative variety of carcinoma, cellulitis may result from absorption of infectious products from the cervix; actual extension is, generally, also present. Macroscopic vaginal extension, even from extremely small cervical lesions, are generally accompanied by carcinoma in other areas beyond the confines of the cervix, and all such cases should be classed in Stage III. In this stage, glandular enlargement can often be demonstrated, especially by rectal palpation. Stage IV—This represents the terminal stage of the disease. Large craters, extensive vaginal extension, absolute fixation, and often vesicovaginal or rectovaginal fistulæ are present.

The division of recurrences into early, moderately advanced, and advanced requires no description.

Before determining the extension of any case of cervical carcinoma, bimanual vaginal and rectal, as well as cystoscopic and proctoscopic, examinations should be performed.

To the above classification may be added the group of complicated carcinomata. By this is meant cases in which the cancer is associated with some general disease, such as pulmonary tuberculosis,

cardiac disease, or some other condition which in itself renders the patient a poor operative risk.

Treatment.—Prophylaxis: Repair of cervical lacerations, dissemination of knowledge regarding the significance of the early symptoms of cancer, and periodic examinations during the "cancer age" are the most important prophylactic measures. The close etiologic relationship which exists between lacerations, cervicitis, and the development of carcinoma has been previously pointed out. Ninety per cent of carcinomata develop on lacerated cervices. Less than 2 per cent develop upon cervices which have been repaired. In cases where cervical repair has been properly practiced, carcinoma develops once in about 1,750 cases.[19] Cervical lacerations are often productive of unpleasant symptoms, in addition to being etiologic factors in the production of cancer. Cervical repairs are extremely satisfactory operations as regards the relief of symptoms, and the operative mortality is almost *nil*. Immediate repair should be undertaken in practically all cases in which proper aseptic precautions are practicable. Secondary repairs should be practiced in all cases where the lacerations produce symptoms, or where laceration is a factor in producing chronic cervicitis.

Early recognition of cervical cancer is the most important prognostic factor in the treatment of this

disease. In a proportion of late cases, delay in securing adequate treatment is undoubtedly due to ignorance or carelessness of the physician. With improved methods of medical education and a more widespread knowledge of the urgency of early diagnosis, such instances are becoming less frequent. No matter how capable the medical profession may be, it is impossible to treat the patients properly unless they seek medical advice. This they fail to do at a sufficiently early date, in the majority of cases. Dissemination of medical knowledge is necessary regarding the importance of thorough and immediate investigation of symptoms which may indicate the presence of an early cancer. This fact is apparent to all students of the subject. The difficulty lies in spreading such knowledge without producing widespread cancerphobia.

To attain this end we must repeatedly call attention to the fact that atypical bleeding or discharge occurring in the cancer age requires immediate investigation to determine its cause; that these symptoms may be caused by various conditions and not necessarily by cancer, but that such may be the case, and that cancer is curable in its early stages. Unfortunately, pain is a late symptom of cervical carcinoma. It is said that the medical knowledge of one generation becomes the lay knowledge of the next, but it is a fact that at present the large majority

of patients suffering from cervical cancer have not been aware of the significance of these early symptoms. Discouraging as it may be to those interested in the prophylaxis of this disease, there is a not inconsiderable group of cancer patients who do not belong in this class and who are well aware of the danger symptoms of early carcinoma, but disregard the warning signs, for fear or other reasons. Too often a patient suffering from atypical bleeding at the menopause attributes this to the "change of life." The menopause frequently results in atypical bleeding, which ceases after a variable period of time, amenorrhea becoming established. Thus the dangerous belief becomes established in the lay mind that irregular bleeding heralds the advent of the menopause. Perhaps nine times out of ten the neighborly advice that the bleeding is merely the manifestation of the approaching "change of life" is correct, and the belief becomes more firmly established with the general population; but the tenth time it occurs the theory is wrong, and the carcinoma reaches the hopeless stage before the patient seeks medical advice.

The advantages of periodic medical examinations have so often been stressed in the medical literature, and are so apparent, that a repetition here is unnecessary. In women, such examinations are doubly important at the cancer age, and should include

a thorough investigation of the genital tract. There are, however, many factors working against the absolute success of such examinations: the rapidity of development of cancer beyond the operable stage; the difficulty of diagnosis of certain forms, such as the interstitial variety; and the impracticability of examining all women sufficiently often to insure recognition of the lesion in its early stage —these three factors are apparent. Still, this does not prove that periodic examinations during the cancer age—even if such examinations were made only once each year—would not be of some benefit, and that they would not result in the detection of a proportion of early and hitherto unsuspected cases. Such examinations could also be used to impress on patients in general the importance of investigating all suspicious symptoms, and this should be one of their most important functions.

In conjunction with prophylaxis, the unfortunate term "precancerous" has crept into the literature on this subject. This term is dangerous, alarming, and inaccurate. A lesion is either cancer or is not cancer. It is true that there are certain conditions which favor the development of carcinoma. On the other hand, there are hundreds of thousands of badly lacerated cervices in which cancer does not develop. Until more is known of the cause of cancer, no one can safely state which

will and which will not develop cancer. The diagnosis of cervical carcinoma is generally easy by clinical methods in the moderately advanced cases, and can, with the aid of the microscope, be definitely arrived at in the earliest known stage. The term "precancerous" opens an avenue for the performance of many unjustifiable operations. It is sometimes used as a shield when radical operations have been performed upon mistaken or loosely made diagnosis, which a little greater preoperative study could have positively cleared up and the patient been entirely relieved by a less hazardous procedure. There is no excuse for the performance of a radical hysterectomy for a lacerated cervix. At the present time, we have no proof that there is a precancerous stage. There are conditions which are known to predispose to the development of cancer, but this is quite a different thing from precancerous. Precancerous implies that no cancer is present, but that cancer will subsequently develop. For many reasons it may be impossible for both clinician and pathologist to state with certainty whether cancer is or is not present. They may suspect cancer of being present. This is very different from making a diagnosis of "precancerous."

Operative Treatment.—Prior to the advent of radium, hysterectomy was the recognized treatment for all Stage I and II carcinomata, and the more

advanced cases were treated by cautery, acetone, and other more or less palliative procedures. On account of the unsatisfactory end-results following the ordinary hysterectomy, more radical operations were developed, notably those of John G. Clark, Emil Reis, Mackenrodt, and Wertheim. Clark soon abandoned the operation because of the high operative mortality and morbidity, and because he found the end-results not to justify the increased operative risks. The Wertheim operation had a greater vogue, and is still preferred in some clinics for the treatment of early cases. The Wertheim operation is one of the most difficult of intraperitoneal operations, and should be attempted only by the skilled pelvic surgeon. Except in the extremely early stage, cervical carcinomata are practically always the seat of pathologic micro-organisms, often of a most virulent type. For literature see the recent paper of Grandclaude and Liégeois.[20] Even in the best hands, the immediate operative mortality is from 12 to 22 per cent. The combined statistics of Martzloff,[21] Mayer,[22] Cobb,[23] Graves,[24] Bonney,[25] Peterson,[26] Schweitzer,[27] Davis,[28] Giesecke,[29] and Bumm,[30] comprising over 2,580 cases of carcinoma of the cervix subjected to the radical operation, show an operative mortality of 15.05 per cent. These operations were performed by skilled pelvic surgeons; in ordinary hands the mortality would certainly

have been higher. The proportion of ureteral and other forms of fistula following the radical operation is high. Ewing [31] states that Mackenrodt's original 72 per cent of successes fell, first to 42 per cent, then to 22 per cent, and finally to 12 per cent, and that Wertheim's statistics suffered a similar revision. Evident discrepancies exist between the claims made of permanent cures, as by Mackenrodt, 58 per cent, and V. Rosthorn, 2.65 per cent. Lynch [32] states that, if operation is to be employed, nothing less than the most radical procedure is justifiable, and undoubtedly many so-called Wertheim or Mackenrodt operations are performed which are nothing more than ordinary hysterectomies, and that relatively few surgeons are capable of performing these extremely radical operative procedures. A careful analysis of end-results has shown that, when the carcinoma has extended beyond the cervix, the end-results have been extremely unsatisfactory, regardless of the type of operation, and the more carefully and exhaustively such statistics are analyzed, the fewer are the successes. The Wertheim type of operation has never been extremely popular with American surgeons, and the general trend of today is away from such radical surgical procedures. This feeling is not due to the high operative mortality and morbidity, but to the fact that the end-results are not sufficiently

satisfactory. In the Stage I cases the radical operation yields about the same proportion of five-year salvage as does radium irradiation. Thus, in Stage I cases, von Fruque records 80 per cent of five-year successes following the radical operation, and von Seuffert [33] a similar proportion following irradiation, to cite two of the most favorable reports. The average surgeon cannot hope to secure these results. Polak [34] states that, in New York, 20 per cent of cases are seen in Stage I (operable stage); in Philadelphia we see less than 10 per cent. Hence, operability is a somewhat arbitrary standard, as what one surgeon considers operable another may consider inoperable. All agree, however, that the proportion of cases observed in early stage is small. For all but the Stage I cases, irradiation is far better than operation.

Radium Irradiation.—Preliminary treatment: This comprises the usual preoperative physical examination, including examination of the heart, lungs, blood pressure, urine, and blood. If the hemoglobin is below 40 per cent, a transfusion is indicated. The preliminary studies and treatment should be performed promptly in order that the treatment of the carcinoma may be instituted with as little delay as possible.

Although irradiation may be performed without anesthesia, a general anesthetic is decidedly prefer-

able and should be employed as a routine. A general anesthetic permits of a more thorough examination and more accurate diagnosis, especially as to the extent of the disease and, as a result, the subsequent treatment may be more efficiently administered to areas of extension which may have been undetectable without the relaxation secured by the anesthetic. The actual application of the radium is also facilitated. In Stage II and III cases, it is sometimes difficult to locate the cervical canal, which is an important point in the application of the radium. The bladder and rectum can also be safeguarded better if a general anesthetic is employed. Morphine sulphate, gr. 1/6–1/4, is administered hypodermically one hour before the operation. Nitrous-oxide anesthesia is satisfactory for most cases. If, for any reason, there is marked rigidity, or if the examination is difficult, the nitrous oxide may be supplemented by a few inhalations of ether in order to secure relaxation. The examination should be thorough and it is better to submit the patient to the slightly greater discomfort of ether than to be uncertain regarding the palpable findings. It is important to determine the extent of the growth as far as possible.

Operation.—Stage I: For those cases in which the cervix is short, situated high in the vagina and cannot be pulled down, or in which the upper va-

gina is narrow, irradiation without trachelectomy is employed. At least 2,400 mg.h. is given at the first treatment, 1,200 m.g. being applied within the canal and the remainder to the vaginal surface of the growth or in the surrounding tissue. The bladder and rectum are pushed back, out of the field of irradiation, by means of a gauze pack. If it is impossible to pack back the bladder satisfactorily, it may be separated from the cervix for a few centimeters prior to the irradiation. After the removal of the gauze pack and radium, the bladder drops back into place and no stitches are required. If the cervix can be drawn well down, and it seems likely that all the carcinoma can be removed by a high trachelectomy, this operation is preferred. The bladder is separated as already indicated. The amputation is performed with the actual cautery, and the radium applied to the canal, the cored-out cervical stump, and the periphery of the cervix. No attempt to close the cervical wound should be made. Convalescence is longer if amputation of the cervix is performed, but, in my experience, the end-results are distinctly better. Trachelectomy permits more accurate application of the radium, and may in itself be curative in few cases. It is important to prevent distention of the bladder during the period of irradiation. Some patients are able to void and these should be given an opportunity to do so at

least once every four hours. If it is impossible to empty the bladder naturally, catheterization should be employed every sixth hour while the radium is in place. Some operators employ a self-retaining catheter during the period of irradiation, and this is always advisable if a reliable special nurse is not available, or if the gauze packing has been so placed as to make catheterization difficult. In the simple irradiation cases, the patient is allowed out of bed on the third or fourth day, but when a trachelectomy has been employed a somewhat longer convalescence is required. The postoperative treatment consists in careful routine examinations at intervals of three weeks. These should be performed by the operator himself, and should never be delegated to an inexperienced person. In early cases a second irradiation is generally advisable ten to twenty-one days later, a dosage similar to that utilized at the initial treatment being employed. Careful watch should be kept for any areas which may have been insufficiently treated, and immediate irradiation applied if such an area is discovered. Postoperative observation is extremely important, and much may be learned regarding the prognosis and requirements for second or even third treatments by the reaction of the area to the initial irradiation.

Stage II, or border-line, cases are given the same treatment as Stage I cases, except that trachelec-

tomy is not routinely employed. In the case of papillary tumors which interfere with the accurate application of the radium, it is advisable to remove the obstructing growths with the cautery. The indications for subsequent treatments are similar to the Stage I cases.

Stage III, or definitely inoperable, cases, are given a single dosage of 2,400 mg.h., provided that this can be done without undue risk of producing a rectovaginal or vesicovaginal fistula. Only a small proportion of these patients can be ultimately cured, and the chief object is palliation. In some cases better effects can be produced by repeated applications of small quantities of radium. Much depends upon the extent and area involved, and upon the reaction of the individual tumor to the radium. It is generally advisable to remove the papillary portion of the tumor with the cautery, in order to determine the extent of the underlying growth and permit safe and accurate application of the radium.

Stage IV cases are unsuitable for irradiation. These patients are doomed, and irradiation only adds to their discomfort. Cleansing deodorant douches and irrigations are indicated, as well as the employment of hypnotics to control the pain. The coal-tar products, opium suppositories, opium by mouth, and, finally, morphine hypodermically, should be employed in the order named. The point

to remember is that enough of the hypnotic should be used to control pain and yet a reserve maintained for the final stage of the disease. Nurses and internes are often prone to withhold the opium derivatives or give them in too small quantities. Whereas such drugs should not be administered unnecessarily, sufficient should be used to relieve the pain. The patients are doomed, and no injury can be done by giving even large doses of morphine. Patients vary markedly—some may be carried through to the end with small doses, while others require much larger amounts. The indication is not the amount of the drug, but the relief of suffering. A modified twilight sleep employing morphine or scopolamine is useful in the terminal stage of some cases in which large doses of morphine alone are ineffective.

Stage V cases or recurrences may be subdivided into V-A, V-B, and V-C, according to whether the recurrences are small, medium, or large in size. The treatment varies with the case. Many V-A cases can be cured. Emanation and the use of deep X-ray therapy are often especially valuable for these cases.

When the recurrence is in the upper vagina following a panhysterectomy, the possibility of a loop of intestine being adherent on the peritoneal side of the lesion must be borne in mind. The bladder

may also be injured by the injudicious application of radium. In some instances it may be advisable to make a small incision in the vagina to determine the condition. This is preferable to treating the recurrence inadequately, or to incurring a severe radium reaction to an adherent loop of intestine or to the bladder. Because of the greater accuracy made possible by their use, radons are often used in preference to the actual radium in this class of cases.

Carcinoma of the Cervix with Pregnancy.—This is an infrequent combination, but cases are occasionally observed.[35] The diagnosis in the early stage of the carcinoma is more difficult than in the non-pregnant patient. The hemorrhages are sometimes attributed to a complication of pregnancy, and the patient treated for threatened abortion. If carcinoma is suspected, the physician often hesitates to perform a biopsy for fear of inducing an abortion. On the other hand, eversions become extremely vascular, often bleed readily on slight trauma, and thus simulate carcinoma. Furthermore, in the case of badly lacerated cervices, the discharge is prone to be augmented as a result of the pregnancy, adding an additional factor to the difficulties of diagnosis. It is needless to state that any hemorrhage occurring in the pregnant woman should be carefully investigated to determine its cause, and that, even in the non-malignant case, it is an ominous

symptom, suggesting a threatened abortion, premature separation of the placenta, or placenta prævia. As previously stated, carcinoma in the presence of pregnancy is prone to run a more rapid course, and to give earlier metastases than in the non-pregnant. Not only is the diagnosis of the early case more difficult and the treatment more complicated, but the prognosis is somewhat less favorable. The patients are usually considerably below the average cancer age and, as carcinoma in young individuals is usually more malignant, this in itself makes the prognosis less satisfactory.

The treatment required varies with the advancement of the pregnancy and the stage of the carcinoma. In the early months of gestation, the uterus should be emptied and all efforts directed toward effecting a cure of the woman. In the last few months it is sometimes justifiable to delay treatment of the carcinoma for a few weeks in the interest of the child, especially when the carcinoma is discovered in an advanced and hopeless stage. In these cases Cesarean section is generally indicated.

The work of Douglas P. Murphy has amply proven the ill effects of therapeutic uterine irradiation either by radium or the X-ray upon the fetus. Even if the child is saved, the chances of maldevelopment—idiocy, microcephaly—are very great

and are an added reason for disregarding the life of the child.

Treatment.—During the first three months of pregnancy the uterus should be emptied, and the carcinoma treated as previously indicated. Anterior vaginal hysterotomy or curettage may be employed for the evacuation of the uterus. The former is especially suitable when both the pregnancy and the carcinoma are in an early stage. The irradiation may be performed at the same sitting. If the uterus is not emptied, the course of the disease is prone to be more rapid and malignant. Dystocia, severe laceration of the cervix, and hemorrhage are prone to occur, and the likelihood of the child being a microcephalic idiot and suffering from some other malformation the result of the irradiation should be considered. Furthermore, the treatment of the cancer may, itself, cause abortion. When the cancer is advanced, evacuation of the uterus is generally indicated, as the mother is likely to die before a living child can be born, even if the mother is altogether disregarded and all efforts directed toward securing a living child.

When the pregnancy is advanced to the fourth month or more, cases must be individualized, as there is then naturally a greater chance of securing a living child by a Cesarean section before term. Only in rare instances should delivery *via* the va-

gina be attempted, as this course tends to produce severe lacerations, hemorrhage, and sepsis.

During the later months of pregnancy, a Cesarean section and irradiation of the cancer is the most satisfactory treatment. Karg [36] collected from the literature the records of six cases in which pregnancy followed carcinoma of the cervix, all of which had been treated by irradiation with radium. Pregnancy following carcinoma is extremely infrequent, for even if the patient survives, the irradiation generally produces a permanent sterilization. The same author analyzes the results secured by radium irradiation in ten cases of carcinoma of the cervix associated with pregnancy and as a result of his study comes to the conclusion that irradiation is superior to operation for these cases.

Carcinoma of the Cervical Stump.—Carcinoma may develop in the cervical stump which remains *in situ* after a supravaginal hysterectomy, and this fact has been used as an argument for the advantages of the routine performance of panhysterectomy. A careful survey of the situation shows that, while such cervices are by no means immune, they are, on the other hand, no more likely to become the seat of carcinoma than are those upon which supravaginal hysterectomy has not been performed. The operation of supravaginal hysterectomy is more easily performed, shows a lower

operative mortality and morbidity, and does not result in shortening of the vagina. This subject will be dealt with more in detail under the heading of "Treatment of Uterine Myomata." In the John Goodrich Clark Gynecological Clinic of the University of Pennsylvania, our custom has been to reserve panhysterectomy for those cases in which the cervix is lacerated or the seat of a cervicitis, as it is well proven that cancer rarely develops in a normal cervix. This practice greatly reduces the already low incidence of the disease in this area. The treatment of cancer of the cervical stump is governed by the same general principles as if the fundus were present. An added danger, however, lies in the possibility of a loop of intestines being adherent to the top or posterior portion of the stump. If there is any doubt in this respect, a small incision in the cul-de-sac may be made to determine the intraperitoneal condition, and to relieve the adhesion if it is found to exist. The shortness of the cervical stump and the postoperative narrowing of the vagina may also render the irradiation somewhat more difficult. Emanation is often preferred to the actual radium, and applications on the vaginal surface of the tumor are safer than applications within the canal. Separation of the bladder from the anterior surface of the cervix is often desirable.

X-Ray in the Treatment of Cervical Carcinoma.

—It is generally conceded that X-ray therapy alone is unsatisfactory for the treatment of cervical carcinoma.

Many operators employ X-ray in combination with radium for this condition, but the advisability of such a combination is still a matter of discussion. At first glance such a combination would seem to possess many advantages, but a study of statistics fails to definitely confirm this belief. It is certain that the enthusiastic reports which at first emanated from some of the European clinics have not been realized in this country, and many surgeons who formerly employed both X-ray and radium have now discontinued the use of the former. A further study of this subject is, however, required. The argument that the X-ray can at most do no harm is, however, fallacious. In 1922 Zweifel stated that the results from the Doederlein [37] clinic were improved 6 per cent by the use of the X-ray. Amann [38] also reported a marked improvement. Some equally qualified observers have abandoned the use of the X-ray.

Postoperative Treatment.—For the first twenty-four hours hypodermic injection of small doses of morphine are advisable to control pain or discomfort. Discomfort is due chiefly to packing, the presence of the radium within the uterus, posture during operation, and the effects of anesthesia. Care

must be observed to prevent overdistention of the bladder during the period when the radium is in place. Unless a permanent catheter is employed, catheterization should be performed every fourth or sixth hour, according to the amount of urine secreted, provided the patient cannot void. Patient should be encouraged to move from side to side, and may sit up in bed or assume the Fowler position, according to which gives the greatest comfort. A varying degree of nausea, or even vomiting, is generally present during the period of irradiation. This generally disappears as soon as the vaginal packing is removed. It has been claimed with some reason that the degree of reaction may be taken as a guide to the radiosusceptibility of the tumor. Destruction and absorption of the cancer-cells probably do cause some disturbance, as has been pointed out by Schmitz [39] and others. Ewing [40] believes that the ideal dosage is capable of restraining the growth of the neoplastic cell without causing either autolysis or necrosis; however, tissue breakdown does occur. Reactions are satisfactorily treated symptomatologically, and by the administration of copious quantities of fluid and stimulation of the action of the kidneys and bowels. Acidosis requires alkalinization, and alkalosis calls for mild acids, such as lemon or orange juice. Nausea and vomiting may be relieved by morphine and atropine, or

in severe cases by lavage. Hypodermoclysis, or even transfusion may be employed in the more severe cases. The rectum should not be distended during the period of irradiation.

The diet should be liquid for the first twenty-four hours, soft for the second and third day, and after that a full diet may generally be given. Unless trachelectomy has been employed, the patient may be out of bed on the third day and go home on the fifth. When trachelectomy has been performed, the duration of hospitalization is generally about ten days, and convalescence at least twice that long.

A second and, in some cases, a third irradiation is advisable in most of the early cases, and adds considerably to total number of five-year cures. The indication as to whether more than one irradiation is advisable depends upon the locality and character of the neoplasm, and its reaction to the first treatment. Generally there should be an interval of from one to two weeks between the first and second treatment, and a similar or slightly longer interval between the second and third, if a third irradiation is decided upon. If the interval is too short, it is impossible to determine the amount of local reaction resulting from the first treatment; if it is too long, the formation of connective tissue mitigates against the success of the treatment, and contrac-

tures of the vagina develop, making it more difficult to adequately safeguard the bladder and rectum. The entire question of subsequent treatment is one which requires considerable judgment and experience.

Innumerable statistics regarding the ultimate salvage secured by irradiation in cases of carcinoma of the cervix could be quoted. Lynch and Maxwell,[41] Greenough,[42] Clark and Ferguson,[43] Ward and Farrah,[44] Heymann,[45] Regaud,[46] and Clark and Norris,[47] to mention only a few who have made careful analytical studies of the subject.

The operative mortality following irradiation is less than 0.5 per cent. In the John G. Clark Gynecological Clinic at the University of Pennsylvania, the operative mortality in the last series (520 cases) was 0.38 per cent. The total five-year salvage, including cases in all stages of the disease, varies from 15 to 30 per cent, according to conservative estimates. Ward[48] in his last series showed 24.6 per cent alive at the end of five years; Schmitz, 14.5 per cent; Muhlmann,[49] 10 to 20 per cent; Lahm,[50] 34 per cent. Treated during Stage I, about 65 per cent are alive at the end of five years; Stage II, 30 per cent; Stage III, 5 to 10 per cent; Stage IV, 1 per cent; Stage V-A, 30 per cent; Stage V-B, 10 per cent; and Stage V-C, 1 per cent.

The radical panhysterectomy as developed by

Wertheim is applicable for the Stage I cases, and gives about the same proportion of five-year cures as does irradiation.

In all other cases irradiation is superior. Nothing short of the Wertheim operation is justifiable. This operation consists in the removal of the ovaries, tubes, entire uterus, a wide vaginal cuff, and the parametrial tissue and lymphatics, the latter being excised *en masse* and not removed separately. The ureters are isolated, and the uterine arteries ligated close to their origin. Few surgeons have sufficient experience to perform the Wertheim operation. Many so-called radical hysterectomies fall short of the best teachings regarding this operation. Even in capable hands, and practiced only upon selected cases, it is a formidable operation and associated with a high operative mortality and a high morbidity, as instanced by injury to the ureters, bladder, rectum, and other vital structures. The operation requires extensive dissection, produces much trauma, results in a wide exposure of cellular tissue, and opens avenues for infection and peritonitis. Virulent streptococci are present in the majority of cervical carcinomata. Furthermore, the operation is time-consuming and even in the best hands results in considerable loss of blood, and in shock and other factors contributing to high mor-

tality and morbidity. It would seem that hysterectomy has been thoroughly perfected, and there has been ample time to study the end-results secured by it. The general trend of American surgeons is away from hysterectomy in the treatment of cervical carcinoma, not so much because of the high operative mortality and morbidity, as because the end-results have been found unsatisfactory. Irradiation is a relatively new form of treatment, and the methods of its application are still being improved upon. Reports from the current literature indicate that more favorable results are now being secured than at the time Greenough made his survey for the American College of Surgeons.

SARCOMA OF THE CERVIX

Sarcoma of the cervix is a rare tumor. The combined statistics of Piquand,[51] Gessner[52] and Meyer[53] show that sarcoma affects the corpus about fourteen times more frequently than the cervix. Frank[54] estimates that for every sarcoma of the uterus encountered there are from thirty to forty carcinomata. Hurden[55] divides sarcoma of the cervix into two groups according to its morphology: (1) an indefinite group, comprising the ordinary sarcomata; and (2) a group embracing the racemose myxosarcomata.

These tumors may present various macroscopic characteristics: they may be single or multiple, interstitial or diffuse, ulcerative or papillary. On section the spindle-celled sarcoma is usually hard and firm, whereas in the round-celled forms it may be soft, homogeneous, friable, and vascular. The sarcomatous tissue may frequently be seen to penetrate the surrounding tissue in an irregular manner, and to present a different consistency and appearance than the normal cervical structures. In the early stages the tumor is covered by normal cervical epithelium, but as the condition progresses the growth tends to break down and become ulcerative. Perhaps the most frequent form of sarcoma is that which develops in a cervical stump after a supracervical hysterectomy for what was believed to be a myoma. In these cases reëxamination of the original tumor will generally show that the growth was in reality a spindle-celled sarcoma or a myoma undergoing sarcomatous degeneration.

Sarcoma is probably of myogenic origin, and round, spindle, giant, and mixed-cell types may occur. Melanosarcoma (metastatic in origin), alveolar sarcoma, and angiosarcoma have been observed. Cervical polypi may undergo sarcomatous degeneration. In the adult, cervical sarcoma is often mistaken for carcinoma, myoma, or polypus, and a

correct diagnosis arrived at only as the result of a histologic examination. Cervical sarcomata vary markedly in the degree of their malignancy; thus in the encapsulated interstitial and spindle-cell varieties, where growth is slow, metastasis develops late. Tumors composed of small round cells are highly malignant, and may give rise to distant as well as local metastasis. In histologic structure the round-cell variety is often suggestive of an endothelioma.

The so-called racemose myxosarcoma is in many respects similar to the myxosarcoma which occurs in the vagina of infants and children. It is a rare tumor, often appearing in the form of polypoid or grapelike masses. It is extremely friable, bleeds easily, grows rapidly, and gives rise to early metastasis.

Treatment.—The treatment is essentially similar to that required for carcinoma. A high trachelectomy, performed with the cautery, and irradiation of the stump, as described under the treatment of cervical carcinoma, probably constitute the most satisfactory procedure. If the body of the uterus is involved, and the parametrium, bladder, and rectum apparently are normal, hysterectomy and bilateral salpingo-oöphorectomy, followed by deep X-ray treatment, are indicated.

ENDOTHELIOMA AND PERITHELIOMA OF THE CERVIX

These are rare tumors, some authorities even denying their existence. Many so-called endotheliomata prove, upon careful study, to be sarcomata. In 1916 Dorland reviewed the literature on this subject and collected thirty cases, of which sixteen were cervical. Clinically, these tumors resemble sarcomata. The same treatment should be employed.

REFERENCES

[1] Findley, quoted by Frank, *Gynecological and Obstetrical Pathology*, New York and London, D. Appleton & Co., 1922, p. 279.

[2] Rosenstern, quoted by Ewing, *Neoplastic Diseases*, Philadelphia and London, W. B. Saunders Co., 1928, p. 585.

[3] Engelhorn, *Cent. f. Gynäk.*, 1908, pp. 13, 278.

[4] Glockner, *Ztschr. f. Geburtoch. u. Gynäk.*, 1908, pp. 63, 182.

[5] Kroemer, *Arch. f. Gyn.*, vol. lxxiii, p. 57, quoted in Ewing, *Neoplastic Diseases*, Philadelphia and London, 1919, p. 539.

[6] Kundrat, quoted by Ewing, *loc. cit.*, p. 540.

[7] Healy, W. P., and Cutler, M., *Am. Jour. Obst. & Gyn.*, July, 1929.

[8] Bergonie, Tribondeau, and Récamier, *Soc. de Biol.*, 1905, p. 284.

[9] Martzloff, K. H., *Surg. Gyn., & Obst.*, 1928, xlvii, pp. 2, 183; also *Johns Hopkins Bull.*, 1924, vol. xxxv, p. 370.

[10] Schmitz, Hueper, and Arnold, *Am. Jour. Rœntgenol.*, vol. 16, 30.

[11] Lahm and Roussy, *Rev. Méd. d.l. Suisse Romande.* Geneva, June 25, 1925.

[12] Fluhmann: *Am. Jour. Obst. & Gyn.*, February, 1927.

[13] Norris, C. C., *Am. Jour. Obst. & Gyn.*, January, 1923.

[14] Norris, C. C., *Gynecological and Obstetrical Tuberculosis*, D. Appleton & Co., New York., 1921.

[15] Cullen, T. S., *Cancer of the Uterus*, New York, 1900.

[16] Lubarsch: *Erg. d. allg. Path.*, vol. ii, quoted in Ewing, *Neoplastic Diseases*, Philadelphia and London, 1919, p. 540.

[17] Schmitz, H., *Jour. Am. Med. Assn.*, January 10, 1925.

[18] Greenough, *Surg., Gyn., & Obst.*, 1924, vol. xxxix, p. 18.

[19] Pemberton, F. A., and Smith, G. Van S., *Am. Jour. Obst. & Gyn.*, 1929, vol. xvii, p. 165.

[20] Grandclaude, C., and Liégeois, M., *presse Méd., Paris*, 1928, vol. xxxvi, p. 1271.

[21] Martzloff, *Johns Hopkins Bulletin*, 1923, vol. xxxiv, p. 141.

[22] Mayer, *Zeit. f. Gyn.*, 1920, vol. xiiv, p. 617.

[23] Cobb, *Jour. Am. Med. Assn.*, 1920, li, xxiv, p. 14.

[24] Graves, *Surg., Gyn., & Obst.*, 1921, vol. xxxii, p. 504.

[25] Bonney, *Brit. Med. Jour.*, 1921, vol. ii, p. 1103.

[26] Peterson, *New York State Jour. Med.*, 1920, vol. xx, p. 313.

[27] Schweitzer, *Zeit. f. Gyn.*, 1921, vol. xiv, p. 289.

[28] Davis, *Am. Jour. Surg.*, 1922, vol. i, xxvi, p. 395.

[29] Giesecke, *Arch. f. Gyn.*, 1922, vol. cxv, p. 435.

[30] Bumm, *Zeit. f. Gyn.*, 1919, vol. xliv.

[31] Ewing, J., *Neoplastic Diseases*, Philadelphia and London, 1919, p. 542.

[32] Lynch, F. W., *Jour. Amer. Med. Assn.*, November 20, 1926.

[33] Seuffert, v., *Strahlen-Tiefen-Therapie und ihre Anwendung in der Gynäkologie*. Berlin, 1923, p. 482.

[34] Polak, J. O., *Am. Jour. Obst. & Gyn.*, November, 1920.

[35] Karg, *Monatschr. f. Geburtsh. u. Gynäk.*, 1928, vol. lxxviii, p. 264.

[36] Karg, *Monatschr. f. Geburtsh. u. Gynäk.*, 1928, vol. lxxviii, p. 264.

[37] Zweifel, quoted by von Fraugue, *Muenchen. Med. Wchnschr.*, 1923, vol. lxx, p. 676.

[38] Amann quoted by von Fraugue, *loc. cit.*

[39] Schmitz, H., *Amer. Jour. Obst. & Gyn.*, April, 1924.

[40] Ewing, J., *An Analysis of Radiation in Cancer*, 1924.

[41] Lynch, F. W., and Maxwell, A. F., *Gynecological and Obstetrical Monographs*, D. Appleton & Co., New York and London, 1922.

[42] Greenough, *Surg., Gyn., & Obst.*, 1924, vol. xxxix, p. 18.

[43] Clark, J. G., and Ferguson, L. K., *Amer. Jour. Obst. & Gyn.*, February, 1927.

[44] Ward and Farrah, *Jour. Am. Med. Assn.*, July 18, 1925.

[45] Heymann, J., *Strahlentherapie*, Berlin, 1928, vol. xxix, p. 407.

[46] Regaud, C., *Am. Jour. Rœntgenol.*, 1929. vol. xxi, p. 1.

[47] Clark, J. G., and Norris, C. C., *Radium in Gynecology*, J. B. Lippincott Co., Philadelphia & London, 1927.
[48] Ward, G. G., *Am. Jour. Obst. & Gyn.*, November, 1928, p. 734.
[49] Muhlmann, *Strahlentherapie*, 1923, vol. xvi, no. 1, p. 137.
[50] Lahm, W., *Fortschr. a.d. Geb. d. Röntgenstrahlen*, 1924, vol. xxxii, pp. 142, 168.
[51] Piquand, *Thèse de Paris*, 1905.
[52] Gessner, *Veit's Handbuch f. Gynäk.*, 1st ed.
[53] Meyer, R., *Veit's Handbuch*, l, c.32. 3,1:455.
[54] Frank, R. T., *Gyn. & Obst., Monographs*, D. Appleton & Co., 1922.
[55] Hurden, E., Kelly and Noble, *Gynecology and Abdominal Surgery*, 1907.

CHAPTER III

CARCINOMA OF THE BODY OF THE UTERUS

FREQUENCY.—Carcinoma is the most common variety of malignant tumor occurring in the body of the uterus. It constitutes from about 20 to 25 per cent of all uterine carcinomata, and is, therefore, about one-fourth to one-fifth as frequent as cervical carcinoma. This form of growth is probably the most frequent cause of bleeding after the menopause has been definitely established. Chronic irritation as an etiologic factor in the production of carcinoma has already been referred to. Chronic cervicitis is extremely frequent, whereas chronic corporeal endometritis is relatively infrequent, and, if the tuberculous variety is excluded, is relatively rare. It is probable that these facts have a definite bearing upon the relative frequency of carcinoma of the cervix and carcinoma of the fundus. Cervical and corporeal carcinomata are two distinct varieties of malignant growth, occurring in different types of patients, producing different symptoms, and requiring different treatment. Formerly, the differentiation between these two types of tumor was not

sharply drawn. The importance of recognizing these growths as distinct entities is now well known.

Etiology.—Anything that favors the development of chronic irritation is a predisposing factor to the development of corporeal carcinoma; thus insufficient drainage of the endometrial cavity, such as may develop after the menopause, due to atrophic changes incident to shrinkage, marked flexions, obstructing new growths, such as myomata or polypi, the presence of tuberculous endometritis —all may act as predisposing factors. Much has been written upon the association of fundal carcinoma and myomata, and a general review of the statistics shows that carcinoma is probably slightly more frequent in myomatous than in normal uteri. Certainly the association of these two neoplasms is by no means infrequent.

Pathology.—Corporeal carcinomata may be inverting or everting in type, the latter being somewhat the more frequent. The common site of origin is the upper half of the endometrial cavity, often in one of the cornua. The tumor may, however, spring from any part of the endometrium. It may be polypoid or sessile in nature, or be a diffusely infiltrating lesion. Whether or not the carcinoma originates from the surface or glandular epithelium, it soon exhibits infiltrating characteristics, and in the later stages the surface becomes necrotic and

FIG. 7.—*Adenocarcinoma of the fundus.* A small pedunculated subperitoneal and submucous myoma is present. A benign polyp is present in the cervical canal.

ulcers develop. On section the neoplasm presents a grayish-white or pinkish appearance, and is smooth, homogeneous, semi-translucent, soft, friable, and vascular. The line of demarcation between the neoplasm and the normal tissue is easily discernible with the naked eye, and its tendency to infiltrate the myometrium is a distinguishing feature between carcinoma and a benign polypoid lesion of the endometrium. The surface is bathed in a thin, irritating, and, in the later stages, malodorous discharge. Areas of necrosis and varying sized ulcers may be present. Small areas, or even larger masses of degenerated carcinomatous tissue, are often present upon the surface. These may be yellow, brown, white, or black in color. In advanced cases yellow or white nodules may be present under the peritoneum, due either to a direct extension of the growth or to the result of metastasis. Spontaneous perforation of the entire thickness of the uterine wall may occur, and instrumental perforations during the course of curettage or exploration of the uterine cavity have frequently been reported.[1] The site of metastases varies according to the part of the endometrial cavity attacked. The ovary, inguinal region, and chain of lymphatics lying on each side of the aorta and extending to the adrenal glands may be invaded. In advanced cases the tubes, ovaries, peritoneum, broad ligaments, vagina, or

vulva may be involved. More distant metastases, such as to the kidney, liver, lung or osseous system, may occur. In general, metastasis takes place less rapidly in fundal than in cervical carcinoma, probably due largely to the thick muscular envelop that surrounds the tumor, and because of the fact that the body of the uterus, except for its ligaments, is not attached to surrounding structures.

Histology.—Carcinoma developing within the uterine cavity is nearly always glandular in type, since no squamous epithelium exists normally in this locality. Adenocarcinoma and adenoma malignum are the common varieties. The former presents the usual histologic appearance of a glandular carcinoma. The investing epithelium, in addition to possessing the customary characteristics of malignancy, is reduplicated. New glands of various sizes, lined by multiple layers of epithelial cells, are present. In some areas the reduplication of the epithelium is so marked that solid plugs of cancer-cells are found. In the adenoma malignum this reduplication is less marked, and often only a single layer of epithelium is present. Many specimens vary greatly in different portions of the tumor, some areas possessing the characteristics of the adenoma malignum and others those of the adenocarcinoma.

It is questionable if the differentiation between adenocarcinoma and adenoma malignum is a real

one, and whether it is advisable. Furthermore, no marked clinical difference between the two growths exists. In this work the term adenocarcinoma is intended to include the adenoma malignum type. In rare instances squamous-cell carcinoma may occur. Histologically these tumors resemble the epidermoid carcinomata found in the cervix. Squamous-cell carcinomata in the fundus have been observed by Gebhard,[2] Benckiser,[3] Emanuel,[4] Gellhorn,[5] Norris,[6] and others. Transition types, or adenocarcinomata that contain areas of epidermoid-like carcinoma are not uncommon, and have been recorded by Frank,[7] Ivens [8] and others. Combinations of adenocarcinoma and epidermoid carcinoma of supposedly distinct origin have been recorded by Kaufmann,[9] Emanuel,[10] and Hofmeier.[11]

Adenocarcinomata composed of extremely high columnar epithelium closely resembling that of the normal cervix have been recorded by Cullen,[12] Albrecht,[13] and others. Carcinomata containing psammomatous bodies have been observed by Schmit [14] and Schutze.[15] Combinations of carcinoma and sarcoma occurring as separate tumors or as single tumors possessing the histologic characters of both, have been recorded.[16] It is a significant fact that in many of the recorded cases the metastases have been of the purely carcinomatous or sarcomatous type.

Age.—The average age of patients suffering from carcinoma of the body of the uterus is about 53 years. From this it will be seen that it develops somewhat later than carcinoma of the cervix. The following table presents the age in decades as found in a series of 115 cases occurring in the John Goodrich Clark Gynecological Clinic at the University Hospital:

Decades	
20–30	1 case (29 years of age)
31–40	14 cases
41–50	18 "
51–60	57 "
61–70	21 "
71–80	4 "

Of the 115 cases, 100, or nearly 90 per cent, were 41 years of age or over, and 82, or 71.3 per cent, were 51 years of age or older. The greatest number, nearly 50 per cent, occurred between 51 and 60 years of age. Peterson [17] states that of his patients 73.2 per cent were between 55 and 65, and of Koblanck's [18] series 50 per cent were between 50 and 60. Cullen [19] and Wilson [20] observed similar findings.

Parity.—Childbirth apparently plays but a small part in the etiology of fundal carcinoma. Of the series of 115 cases previously quoted, 26 per cent gave a history of previous pregnancy. Acute endometritis is a common condition following abortion or labor; it rarely, however, becomes chronic, dif-

fering in this respect from the cervicitis, which engrafts itself upon the lacerated cervix. This fact, probably in part, at least, explains the greater frequency of cervical carcinoma, and accounts also for the fact that the latter disease is relatively infrequent in the nullipara.

Symptoms.—Fundal carcinoma is insidious and in the early stages is often silent. The important symptoms are bleeding and discharge. Anemia, cachexia, pain, and, loss of weight are present only in the later stages of the disease, and usually indicate an inoperable and hopeless condition. The evolution of symptoms is generally somewhat slower in women past the menopause than in those cases in which the disease develops during menstrual activity. Alamanni's [21] studies confirm this opinion.

Bleeding.—The characteristic hemorrhage of fundal carcinoma consists of a slight oozing or "spotting" of bright blood, which increases quite rapidly, and tends to follow trauma. The development of hemorrhage in a patient in whom the menopause has been definitely established, and in whom the ordinary pelvic examination is negative, is more likely to be due to carcinoma of the fundus than to any other cause. When the onset of the hemorrhage occurs during or shortly preceding the menopause, the bleeding may often be attributed to physiologic conditions. Although the hemorrhage

often follows trauma, this tendency is less marked in fundal than in cervical carcinoma, due to the protection afforded by the thick muscular envelop of the myometrium. A vigorous bimanual examination, or straining at stool, especially when constipation is marked, is often followed by the discharge from the vagina of a small quantity of bright blood. Patients sometimes attribute the bleeding following defecation to hemorrhoids. This point can readily be determined by inserting a tampon in the vagina prior to defecation. Although the evolution of the symptom is rapid, it is less so than in carcinoma of the cervix.

Even when the growth develops prior to the establishment of the menopause, the hemorrhage is generally of a strictly metrorrhagic type, and unless ovarian involvement or inflammatory lesions are present, menorrhagia is infrequent. As the disease progresses the hemorrhages become more frequent and more prolonged.

Discharge.—As in cervical carcinoma, this is probably the initial symptom. In the early stage the discharge is small in amount, and is often overlooked until hemorrhage develops. The discharge is thin and irritating in nature, and with the advent of necrotic changes in the tumor it becomes malodorous. The discharge is more or less constant, but in the early stage it often collects in the vagina

when the patient is in the dorsal position, and is especially noticeable when she assumes the upright posture. Not infrequently the discharge becomes sanguineous, and in the later stage may be dark or contain small particles of necrotic neoplastic tissue. At this stage the discharge and bleeding usually require the wearing of a pad constantly. In the early or operable stage of carcinoma of the fundus discharge is usually a more prominent symptom than in carcinoma of the cervix and is thinner and less offensive.

A study of our cases shows that in 81 per cent hemorrhage was the primary symptom, and in the remainder the discharge preceded the bleeding. Hemorrhage, however, occurred in all cases at some period. Close questioning will usually reveal the fact that the discharge actually occurred prior to the onset of the bleeding, but was disregarded by the patient. In carcinoma of the fundus hemorrhage registers about 75 points and discharge 25, whereas in cervical carcinoma the relative diagnostic value of these two symptoms is about 90 and 10 points, respectively. As has been stated, pain, cachexia, and loss of weight generally indicate an advanced and hopeless condition.

Diagnosis.—An early diagnosis is of the utmost importance. Many text-books underestimate the malignancy of fundal carcinoma. The total five-

year salvage is about 30 to 35 per cent of all cases. The fundal tumor probably grows somewhat less rapidly than cervical carcinoma, and on account of the thick enveloping myometrium the development of metastasis is somewhat delayed. Except for the ligaments, the fundus is free, and this freedom from attachments probably accounts for more prolonged localization of the neoplasm than when the tumor occurs in the cervix, which is so closely associated with the bladder, rectum, broad ligaments, ureters, and vagina.

The negative pelvic findings may induce a feeling of security in the inexperienced medical attendant, and the fact that the patient is often advanced in years may cause him to hesitate to advise radical treatment. Like many genital carcinomata of the female, carcinoma of the fundus is usually painless in the early stages, and the absence of all discomfort also militates against early recognition. Carcinoma of the fundus often develops after the woman has experienced a period of irregular menstrual bleeding, due to the onset of the menopause, and under such circumstances the hemorrhage is prone to be attributed to a return of the physiologic condition.

Disinclination to submit to a gynecologic examination and the general good health often enjoyed by the patient both contribute to cause delay in seek-

ing medical advice, and account for the late stage in which many of these cases are seen by the surgeon.

Differential Diagnosis.—Carcinoma of the fundus may be confused with a variety of conditions. Discharge and bleeding are two of the most frequent gynecologic symptoms. The onset of carcinoma is insidious, painless, and in many cases almost silent. In the late stages, however, it is readily recognized. During the early stage a positive diagnosis cannot be made without the aid of the curet and the microscope. Although the symptoms of early carcinoma are often sufficiently characteristic to arouse the suspicion of the experienced physician as to the real cause of the lesion, they are by no means pathognomonic.

Uncomplicated myomata of the uterus are the most frequent forms of uterine tumor, and should easily be differentiated from carcinoma. The slow development of the symptoms, the gradual onset of the bleeding, the large nodular character of the lesion, and the younger age of the patient all point to the benign tumor. Small single submucous myomata, especially when undergoing necrosis, may easily lead to confusion.

The frequent association of myomata and fundal carcinoma has previously been referred to, and unless curettage is performed or the uterus is re-

moved, the presence of carcinoma often cannot be determined with certainty. Unless this point is borne in mind, the preëxisting symptoms of the myoma may mask those of the carcinoma, and lead to error in diagnosis. For this reason pelvic irradiation, especially by means of the X-ray, should never be prescribed for women in the cancer age unless the treatment be preceded by a curettage and the curettings submitted for histologic examination.

Endometrial polypi may produce symptoms closely simulating those of carcinoma, and can be differentiated with certainty only with the aid of the microscope. Furthermore, 1 to 2 per cent of all endometrial polypi undergo carcinomatous degeneration.

The so-called *metrorrhagic myopathies*, or functional uterine hemorrhage, when occurring during the cancer age, may also lead to confusion. As the treatment for these conditions consists of curettage and irradiation, it is only necessary to submit the curettings to histologic examination to obtain a correct diagnosis.

Senile vaginitis causes slight irregular bleeding that tends to follow trauma and is associated with a varying amount of discharge. Occurring as it does at the cancer age, the subjective symptoms may be identical with those resulting from an early fundal carcinoma.

As a general rule, to which there are exceptions, malignant uterine neoplasms give rise to metrorrhagias, whereas benign conditions are prone to cause menorrhagias. Slight irregular intermenstrual bleeding is, therefore, of more ominous import than even massive hemorrhages at the normal periods. Of especial significance is the character of the onset, for many of the benign conditions have their origin in an increase of the normal menstrual period, but eventually, in the later stages, lead to irregular and profuse hemorrhages. The duration of the symptoms is also a valuable guide in determining the diagnosis; thus a polypus or a myoma may be present for years, whereas the average life of the patient suffering from carcinoma is not more than two or at most three years without treatment, and generally results in a characteristic clinical picture within from three to six months. If the cancer patient is to be saved, the condition must be recognized early and at a time when the symptoms are generally vague. Diagnostic curettage must be employed. The only alternative is a routine hysterectomy in all suspected cases. This would mean many unnecessary operations, with the accompanying risks and discomforts, or that the growth be allowed to develop to such a stage that clinical recognition can be made with certainty. Curettage is associated with

practically no mortality, and may even be performed under local anesthesia.

The Reliability of Curettage.—The possible sources of error are: (1) the curettage may be ineffectual, and only a part of the endometrial cavity may be curetted; (2) obstructing myomata or other benign conditions may prevent the curet from reaching the carcinoma; (3) carcinoma may be present in one horn of an unrecognized bicornuate uterus, and the normal cavity subject to curettage; (4) the tissue secured by curettage may be lost or confused with other curettings, either in the operating-room or in the laboratory; (5) the pathologist may be incompetent. Proper precautions should be adopted to avoid error. The curettage should be a thorough one, and all the curettings should be preserved. The tissue thus secured should immediately be placed in a fixing solution, properly labeled, and submitted to the pathologist. A careful bimanual examination and the use of the sound and curet should determine the presence of submucous myomata or abnormalities of the uterine cavity. In our own laboratory a triple check-up is employed for all tissue that is being prepared for histologic examination, so that confusion of specimens is practically impossible. The microscopic recognition of fundal carcinoma is not difficult for the experienced pathologist. It must be emphasized, how-

ever, that this is special work. The normal endometrium itself presents many varied pictures besides those that result from oblique cutting and other factors incident to the preparation of the tissue. Furthermore, certain benign lesions may add to the difficulty encountered by the pathologist who is not familiar with gynecologic histopathology. Misinterpretation of the histologic picture is the chief source of error in diagnostic curettage. The macroscopic appearance of curettings from a case of carcinoma of the fundus is generally highly suspicious. The tissue rolls out of the uterine cavity in thick, brain-like masses, and if these are washed carefully in salt solution it will be seen that the surface is not smooth and glistening, as in the normal endometrium, but is often shaggy, and may contain areas of white, yellow, brown, or black tissue, indicating the presence of necrosis. In general the tissue is much more friable and vascular than that of the endometrium. Frozen sections may be made if sufficient tissue is available. If this is positive, the diagnosis of carcinoma may safely be accepted. If the frozen section is negative for carcinoma or the diagnosis is uncertain because of a poor histologic preparation, then the entire tissue should be mounted in paraffin and prepared in the usual manner. One or more blocks should be made, according to the amount of tissue to be prepared,

and these should be cut at different levels in order to be sure that a portion of every fragment of tissue actually is stained and may be examined by the pathologist. Frozen sections are not usually satisfactory for curettings, for only a small amount of tissue may be secured as the result of the curettage, and the important portion may be wasted. Paraffin preparations are, as a rule, better for the purpose than frozen sections. Well-prepared histologic specimens are much more satisfactory. The curettings consist of relatively small bits of spongy, easily infiltrated tissue, and satisfactory paraffin preparations may be secured in from fifteen to eighteen hours or less. Excluding the exceptional case, this is the method of choice. As soon as the curettings are removed from the vagina they should be placed in a 4-per-cent solution of formalin and well shaken in order to avoid the formation of blood clots.

Technic of a quick method of preparing curettings for microscopic examination:

1. Immediately upon removal place all the curettings in a four-ounce bottle which contains three ounces of a 10-per-cent formalin solution. Shake well to prevent clotting. Let stand for one to six hours.
2. Carefully separate all tissue from blood and place it in 95-per-cent alcohol for an hour.

3. Replace with fresh 95-per-cent alcohol for one hour.
4. Transfer curettings to xylol until they become translucent (usually about fifteen minutes).
5. Transfer to melted paraffin (46–50′) in oven for thirty minutes.
6. Transfer to fresh melted paraffin (46–50′) for thirty minutes.
7. Embed in hard paraffin (58–60′).
8. Cut.
9. Dry in oven or on heater.
10. Stain with eosin and hematoxylin.

The paraffin in which the tissue is to be mounted should be hot, so that all the tissue may sink as nearly as possible to the same level. A metal mounting-box is more satisfactory than the paper box so often used. A good plan is to place the melted paraffin and tissue in the mounting-box and then heat the box. This reliquefies all the paraffin and permits the tissue to sink to the bottom in a single layer. When this is done, all the tissue can easily be cut. Care must be exercised not to "cook" the tissue. Even when this method is employed it is advisable to take a section, cut down farther into the block for a short distance, and take another section, until all the tissue has been cut. In this way one may be certain that a portion of every particle of tissue may be subjected to microscopic inspec-

tion. These suggestions are especially applicable when only a small amount of tissue has been secured.

The pathologist should have all the data pertaining to the case, including the menstrual history, and should be warned that there is at least a suspicion of malignancy, in order that he may adopt special precautions. The following table shows the importance of diagnostic curettage, and is formulated from a study of 101 consecutive cases of adenocarcinoma applying for treatment at the John Goodrich Clark Gynecological Clinic of the University Hospital.[22]

CARCINOMA OF THE BODY OF THE UTERUS

Total number of cases 101

	Cases	*Per Cent*
Early stage	24	23.7
Moderately advanced	53	52.4
Advanced stage	24	23.7
Clinical diagnosis positive and correct	57	56.4
Clinical diagnosis doubtful	24	23.7
One case, clinical diagnosis carcinoma of the cervix, but proved fundal in origin		
Clinical diagnosis benign, but proved to be malignant	20	19.8
Clinical diagnosis myoma uteri	15	14.8
Clinical diagnosis metrorrhagia myopathica	2	1.9
Clinical diagnosis hyperplasia of the endometrium	2	1.9
Clinical diagnosis other benign condition	1	0.9

It is a significant fact that of the twenty totally unsuspected cases, fifteen, or 75 per cent, were associated with uterine myomata, and the symptoms of the benign neoplasm evidently overshadowed and masked those of the malignant growth. These fig-

ures also emphasize the importance of performing diagnostic curettage as a preliminary to irradiation for presumably benign lesions. A number of cases that were suspected of malignancy were shown, on histologic examination of the curettings, to be benign. These are not included in this group.

In 58 of these 101 cases a preliminary curettage was performed, and the presumption is that this would not have been done had the diagnosis been assured. This group comprised most of the early cases.

Adenocarcinoma of the Body of the Uterus (Curettings)

Total number of cases	58	
	Cases	*Per Cent*
Clinical diagnosis positive	21	36.2
Clinical diagnosis doubtful	22	37.9
Clinical diagnosis benign	15	25.8

To summarize, it may be stated that, even in the hands of the most careful diagnostician, in at least 20 per cent of the cases a positive diagnosis cannot be arrived at without the aid of the pathologist prior to the removal of the uterus. Furthermore, in the early cases, or in those associated with a benign lesion that produces bleeding, such as myoma, this proportion is nearly doubled.

An attempt has been made to emphasize all the errors that may be made as a result of diagnostic curettage. As a matter of fact, given a competent gynecologic pathologist, these are almost *nil*, and a

correct diagnosis can be arrived at in practically 100 per cent of cases. So far as we know, in our own laboratory, in the last twenty years, we have never made a histologic diagnosis from curettings of a benign lesion that subsequently proved to be malignant, or of carcinoma in which, when the uterus was removed, the histologic diagnosis was not confirmed. These results are probably duplicated in all well-managed laboratories.

The Clark test is of great practical value, and although it lacks the accuracy obtained by curettage, it possesses the following advantages: It may be employed in the physician's office; it requires no especial skill or histologic knowledge, or extensive armamentarium; it involves no loss of time. The technic for making the Clark test is as follows:

The external genitals, the vagina, and the cervix are cleansed thoroughly with an antiseptic solution. Under sight a sterile uterine sound is passed to the fundus of the uterus, and its point is gently manipulated over the entire endometrial cavity. If a friable, vascular lesion, such as a carcinoma, is present, following the trauma a small trickling of blood will be observed to issue from the cervix. An excellent means of employing the Clark test is, after cleansing the vagina, to introduce a Sims speculum and partially to fill the vagina with a 1:2000 bichlorid solution, so that the cervix is immersed in

a pool of this liquid. The sterile sound is then passed and its tip is gently raked over the entire endo-

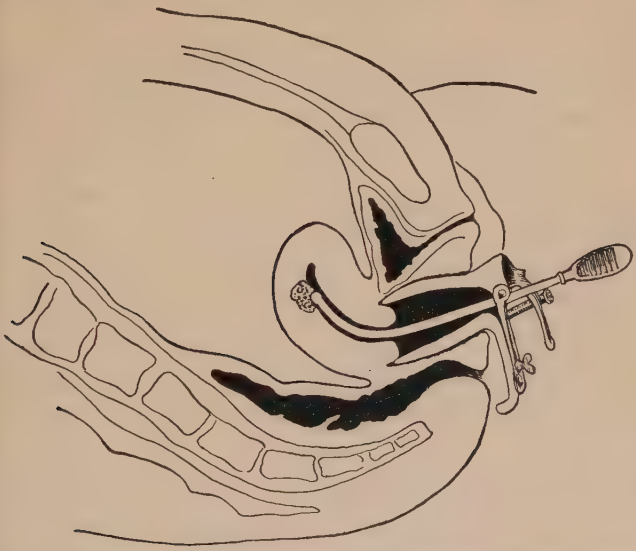

FIG. 8.—*The John G. Clark test for carcinoma of the fundus.* With the patient in the lithotomy position, employing strict asepsis and under sight, a sound is inserted and its tip gently manipulated over the entire uterine cavity. If a friable, vascular growth, such as produced by a carcinoma, is present, the procedure will be followed by a trickle of bright blood from the cervix. The contraindications are lack of asepsis or possible pregnancy. This test may be utilized in the office, requires no especial knowledge or armamentarium, and involves no loss of time. It is not a substitute for diagnostic curettage, and while not pathognomonic is extremely valuable in suspected cases.

metrial cavity. It is well known how a few drops of blood from a nosebleed will discolor a basin of water, and in the same manner a few drops of

blood from this manipulation will be demonstrated in the clear solution in the vagina. In employing this test the cervix should not be grasped with a tenaculum, and absolute asepsis is essential. Nearly all these patients are past the child-bearing age. Obviously, the test should not be employed unless pregnancy can be excluded.

The findings in the Clark test are not pathognomonic of carcinoma, since other pathologic conditions may cause bleeding. If no blood comes from the cervix, this is strongly indicative that no cancer is present. The test rarely fails if cancer is present. Ewing has suggested taking a smear preparation from the fundus, and by this means he has been able to demonstrate, in certain cases, the presence of carcinoma-cells or fragments of the tumor. Kelly employs a small curet and examines portions of tissue thus secured. The Clark test is of especial value on account of its simplicity, and when the findings are positive the test should be followed by a diagnostic curettage. The latter should be thoroughly done, every portion of the endometrial cavity being explored, for the carcinoma may be small, and these early cases are those in which the diagnosis from the clinical symptoms alone is made with difficulty; they are the ones that, if properly treated, offer the best hope of ultimate cure. As most of the suspicious cases are at or past the meno-

pausal age and complain of pathologic bleeding, the curettage should be followed by the introduction of radium into the fundus of the uterus. If the lesion is benign this generally exerts a curative effect. If a carcinoma is present the irradiation tends to destroy the malignant process, inhibits or destroys fragments of carcinomatous tissue which may have been dislodged during the curettage, and in this way checks the likelihood of transtubal dissemination.

A number of arguments have been advanced against diagnostic curettage; thus it has been stated that this operation (1) opens up avenues for lymph and blood metastases to take place; and (2) it may result in dissemination of broken-up particles of the tumor by way of the lumen of the tube. It is true that any trauma to a malignant neoplasm is to be deprecated. Sampson's theory of transtubal dissemination of desquamated epithelium in the production of perforating or chocolate cysts of the ovary possesses many convincing arguments. If it is accepted, it can readily be understood how diagnostic curettage may occasionally result in dissemination of carcinoma by means of the lumen of the tube. The curettage breaks up the carcinomatous growth and undoubtedly leaves fragments of the neoplasm behind free in the endometrial cavity. Uterine spasm following the operation, and espe-

cially if any obstruction to the cervical canal is present, such as may result from an acute flexion or the presence of packing, may result in microscopic particles of the tumor being forced through the lumen of this tube, and as these are probably viable, implantation growths may result. For the last two years, in the laboratory of gynecological and obstetrical pathology in the University of Pennsylvania, all cases in which this form of dissemination might have occurred have been subjected to a rigid examination, and in one case cancer-cells were demonstrated in the ampulla of the tube. We have also had one case in which curettage was apparently followed by this form of metastasis.[23] To obviate such a possibility, the following points should be borne in mind when performing diagnostic curettage: (1) The endometrial cavity should never be irrigated; (2) no uterine packing should be employed; (3) the dilatation should be a thorough one, in order to secure free drainage after the operation and to avoid all piston-like action when inserting the radium-bearing tube; and (4) intra-uterine irradiation should be administered. The well-known lethal action of the radium rays upon detached cancer-cells is of especial value in these cases.

The dangers of diagnostic curettage are more theoretical than practical. As previously stated, in

many cases the formulation of a positive diagnosis by clinical means alone is impossible, and the proportion of correct diagnoses decreases in direct ratio to the earliness of the lesion. Hence, if diagnostic curettage is not employed, it follows that many non-carcinomatous uteri will be removed and needless operations performed, or if the surgeon elects to delay operation until characteristic clinical symptoms develop, more advanced lesions will result and a smaller number of cures be effected. In our cases we found that the group upon which diagnostic curettage was performed as a preliminary measure to hysterectomy actually gave a higher three-year salvage than in the cases upon which hysterectomy alone was practiced.

THREE-YEAR HYSTERECTOMIES ONLY, OR DIAGNOSTIC CURETTAGE IMMEDIATELY FOLLOWED BY HYSTERECTOMY

Number of cases	35
Percentage alive at the end of three or more years	37.5

HYSTERECTOMY PRECEDED BY CURETTAGE TWENTY-FOUR OR MORE HOURS PREVIOUSLY

Number of cases	22
Percentage alive three or more years	40.9

In considering these results it should be remembered that the group which was submitted to diagnostic curettage probably consisted of earlier cases than those treated by immediate hysterectomy. At all events, these figures show that, when properly performed and safeguarded by the application

of radium, the operation is not markedly detrimental to the ultimate outcome.

Treatment.—The treatment of choice for all cases in which the carcinoma is confined macroscopically to the uterus consists of panhysterectomy and bilateral salpingo-oöphorectomy, which should be performed as soon as the diagnosis has been established. In the John Goodrich Clark Gynecologic Clinic postoperative deep X-ray therapy has been reserved for inoperable cases, or for those in which complete operation is prohibited. In view of the favorable results that have been reported during the last year or two in the treatment of this form of carcinoma by irradiation alone, it is reasonable to assume that routine postoperative X-ray treatment may increase slightly the ultimate proportion of five-year salvages.

Among our own 115 cases previously referred to, 10 were treated by diagnostic curettage and radium only. The follow-up showed that of this number 5, or 50 per cent, were alive at the end of three or more years. This number is too small from which to draw conclusions. However, the recently published statistics of Hayman indicate that irradiation is more successful in these cases than was formerly believed to be the case. In a comparative study Hayman, in six clinics, found a total of 271 cases treated by irradiation. Of this group, there

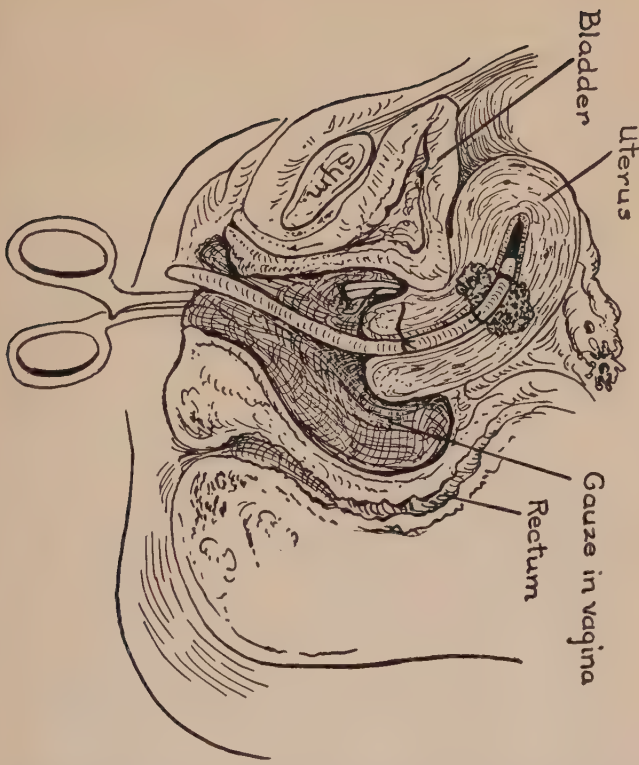

FIG. 9.—*Showing the method of maintaining the radium-bearing rubber tube in the uterus.* A similar method is employed when intracervical applications are used. The stitch is passed through the cervix and without knotting is grasped by a hemostat and cut short. When the vaginal gauze pack is removed the hemostat is released and the radium withdrawn.

was a five-year salvage in 33.6 per cent. At the Radiumhemmet in Stockholm, under the direction of Forsell, 20 of 46 cases, or 43.5 per cent, were well at the end of five years. Fundal carcinoma is usually made up of a moderately adult type of epithelial cell, and for this reason, if the best results are to be secured, a dosage of not less than 4,500 mg.h. of radium irradiation should be given. One of the difficulties attendant upon irradiation is the accurate placing of the radium. It is generally preferable to apply 2,400 mg.h. and repeat once or twice at weekly or ten-day intervals. Although operation is the method of choice, irradiation holds out some hope for cases in which hysterectomy is contraindicated, and it is, moreover, an excellent palliative even in advanced cases. Furthermore, irradiation tends to prolong life. One application of not less than 2,400 mg.h. should always be employed at the time of making diagnostic curettage in patients at the cancer age, but hysterectomy should not be delayed in order to administer further irradiation. Sampson has suggested that the first step in performing hysterectomy should consist of ligation of the distal portion of the tube, in order to prevent the dissemination of carcinomatous cells that might be lying free in the lumen of the tubes during the course of the operation.

On performing hysterectomy a careful intraperi-

toneal examination should be made, and if there is any evidence that the disease has extended beyond the field of operation, or if a thorough histologic examination of the ovaries discloses involvement of these organs, postoperative deep X-ray therapy should be instituted.

Prognosis.—As has been stated, the integrity of the myometrium is the most important factor in making a prognosis. An analysis of our own three-year cases showed that the duration of the symptoms bore a definite relationship to the ultimate outcome.

THE RELATIONSHIP OF THE DURATION OF SYMPTOMS TO PROGNOSIS

Duration of symptoms	Number of cases	Percentage of patients alive at the end of three or more years
6 months or less	24	57.0
7 to 12 months	32	31.2
More than 12 months	28	17.8

Studied from the standpoint of the extent of the disease as determined at operation, and from histologic examination of the specimen removed by hysterectomy, these cases showed the following:

RELATIONSHIP OF THE EXTENT OF THE CARCINOMA TO THE PROPORTION OF CASES ALIVE AT THE END OF THREE OR MORE YEARS

Stage I, or early cases, about 66 per cent, or 2 out of 3 cases
Stage II, moderately advanced cases, about 20 per cent, or 1 in 5 cases
Stage III, advanced cases, 14 per cent, or 1 in 7 cases

Our total number of cases traced for three or more years showed the following results:

Total number of cases	87
Percentage alive	34.8
Percentage alive, no recurrences	27.9
" " with probable recurrences	6.9
" dead, all causes	62.5

The following table shows the three-year results in cases upon whom hysterectomy was performed:

Total number	74
Percentage alive	37.5
" " no recurrence	30.5
" " probable recurrence	7
" dead, all causes	62.5

Cullen [24] records 60 per cent of his cases as alive, but some of these were operated upon only one year previously. Wilson [25] notes only 24 per cent of absolute cures. Nearly all our cases that were treated by irradiation alone were temporarily improved, and in the majority of those who ultimately succumbed life apparently was prolonged and rendered more comfortable. Bailey and Healy [26] report unsatisfactory end-results following irradiation. These observers state that in nearly every case the improvement was only temporary, and evidence of the disease recurred within one year.

REFERENCES

[1] For literature, see Frank, R. F., *Gynecological and Obstetrical Pathology*, New York and London, 1922, and Ballard, C. N., *Surg., Gyn. & Obst.*, 1908, vol. vii, p. 460.

[2] Gebhard, *Path. Anat. d. weib. Sexualorgane*, 1899, vol. xxi, p. 148.

[3] Benckiser, *Ztschr. f. Geburtsh. u. Gynäk.*, vol. xxii, p. 337.
[4] Emanuel, *Ztschr. f. Geburtsh. u. Gynäk.*, 1895, vol. xxxii, p. 477.
[5] Gellhorn, *Ztschr. f. Geburtsh. u. Gynäk.*, 1897, vol. xxvi, p. 430.
[6] Norris, C. C., *Amer. Jour. Obstet. & Gyn.*, 1907, vol. lvi, no. 6.
[7] Frank, R. T., *Trans. New York Obst. Soc.*, 1909-11, p. 338.
[8] Ivens, *Jour. Obst. & Gyn.*, *Brit. Emp.*, February, 1911.
[9] Kaufmann, *Spezielle Path.*, Reimer, Berlin, 1911, vol. ii, p. 1034.
[10] Emanuel, *loc. cit.*
[11] Hofmeier, quoted by Frank, *Gynecological and Obstetrical Pathology*, New York and London, 1922, p. 307.
[12] Cullen, T. S., *Cancer of the Uterus*, New York, 1900.
[13] Albrecht, *Monats. f. Geburtsh. u. Gynäk.*, 1906, vol. ii, p. 280.
[14] Schmit, *Monats. f. Geburtsh. u. Gynäk.*, 1900, vol. ii, p. 280.
[15] Schutze, *Arch. f. Gyn.*, 1905, vol. lxxv, p. 20.
[16] For literature, see Outerbridge, *Am. Jour. Obst. & Gyn.*, vol. lxxv, p. 575, and Frank, R. T., *Gynecological and Obstetrical Pathology*, New York and London, 1922, p. 258.
[17] Peterson, R., *Surg., Gyn. & Obst.*, 1919, vol. xxix, p. 544.
[18] Koblanck, *Veit's Handbuch der Gynäk.*, Weisbaden, 1908, 3, ii, 672.
[19] Cullen, T. S., *Cancer of the Uterus*, New York and London, 1900.
[20] Wilson, Eden, and Lockyer, *New System of Gynecology*, London, 1917.
[21] Alamanni, R., *Riv. ital. di ginec.*, 1928, vol. vii, p. 577.
[22] Norris, Charles C., *Amer. Jour. Obst. & Gyn.*, January, 1923, p. 1.
[23] Norris, C. C., and Vogt, M. E., *Am. Jour. Obst. & Gyn.*, May, 1924.
[24] Cullen, T. S., *Cancer of the Uterus*, New York, 1900.
[25] Wilson, Eden, and Lockyer, *New System of Gynecology*, London, 1917.
[26] Bailey, H., and Healy, W. P., *Am. Jour. Obst. & Gyn.*, 1923, vol. vi, p. 402.

CHAPTER IV

MYOMA UTERI

THE terms "myoma," "fibromyoma," "fibroma," "fibroid," and "leiomyoma" are often used synonymously. Pure fibromata and pure myomata are rarely found in the uterus. On the basis that nearly all these tumors contain both fibrous and muscular tissue, Kelly and Cullen [1] advocate the name fibromyomata. Mallory [2] and Frank [3] declare that the term "fibromyoma" would be applicable to a mixed tumor, but is incorrect when employed to designate simple tumors, such as the myoma of uterus in which the connective tissue acts merely as a supporting structure. They prefer the term "leiomyoma," which designates a mesenchymal neoplasm, usually of slow growth, but sometimes exhibiting malignant tendencies. Among the laity this neoplasm is often spoken of as a "flesh tumor." In England it is usually referred to as "fibroid," and in Germany as "myoma."

Frequency.—Fibromyomata are the most common of pelvic neoplasms. Many are symptomless and their presence never recognized. This is proven by the frequency with which they are first noticed

at autopsy. They are much more common in the colored than in the white race. Myomata are present in 4.3 per cent (Moller)[4] to 20 per cent [1] of all gynecological patients. Kelly and Cullen found that, of all black women coming to autopsy at twenty years of age or over, 33.7 per cent had uterine myomata, while only 10 per cent of the white patients were similarly affected.

Etiology.—The cause of fibromyomata is unknown. They are thought to be derived from the muscularis of the blood-vessels. Other theories attribute their origin to the muscularis, connective tissue of the uterus, and misplaced germ-cells. It has been suggested that heredity may play a part in their development.

Myomata are apparently somewhat more common in nulliparæ and sterile women than in those who have borne children. Young and Williams [5] found that 10.5 per cent of women who had reached thirty-eight years of age were sterile. Kelly and Cullen [1] found 33 per cent of myoma cases sterile; Phillips,[6] 29 per cent; Olshausen [7] 30 per cent; and Lynch and Maxwell [8] 31.5 per cent. From these figures it would seem that myomata are more frequent in sterile uteri, a history of sterility being about twice as frequent in patients with myoma as in others. Another and perhaps more probable explanation is that the sterility and

myomata have a common origin and are the result of malfunction of the ovaries. Furthermore, these tumors tend to produce sterility on a mechanical basis. Uchigaki,[9] in the Gynecologic Institute of the Kyoto Imperial University, conducted an interesting series of experiments which have led him to believe that myomata produce some toxic element, acting upon ovarian follicles and thereby producing sterility.

Graves[10] and Ulesko-Stroganowa[11] state that there is no doubt about the menstrual function being an important factor in the causation of myomata. The fact that these tumors develop only during the menstrual era, that they often are associated with hypertrophy of the ovaries, and that they regress after a bilateral oöphorectomy or irradiation castration, has led to the belief than an abnormal ovarian function is the chief factor in the histogenesis of myomata, especially as women affected by this disease frequently give a history of having begun to menstruate earlier than normal. This theory has perhaps the most sound basis and, in addition to the points already mentioned, is supported by the fact that castration, either with radium or by operation, checks the development of the neoplasm and in many cases leads to marked shrinkage of the neoplasm or disappearance.

The tumors are rarely observed before puberty,

and are most common between thirty-five and fifty years of age. The combined statistics of Frank,[3] Kelly and Cullen,[1] McDonald,[12] and the author, comprising 3,091 cases, present the following age incidence for myoma:

20 to 30 years	13.7	Per Cent
31 to 40 "	40.9	" "
41 to 50 "	35.6	" "
51 to 60 "	6.1	" "
60 years or over	2.8	" "

The youngest patient was twenty years of age, and the oldest seventy-three. The incidence was greatest between the ages of thirty-five and forty years, and in the ten-year age-period from thirty-five to forty-five. Over three-fourths (76.5 per cent) occurred between thirty and fifty years of age.

Myomata are slowly growing tumors, often painless and not infrequently symptomless until they have reached considerable size. The foregoing table is based upon the age at which the tumor was discovered, and whereas some were no doubt silent up to that time and only discovered accidentally, the great majority were recognized after evident symptoms had called attention to the pelvic condition. It is, therefore, probable that the tumors had been palpable for some months, if not a year or more, before they were discovered, and that some of them had been present for a considerably longer

period. These tumors rarely, if ever, develop after the menopause. This fact is of diagnostic value. Sarcomata frequently do originate after this period, and a uterine neoplasm which either originates or exhibits definite growth after the cessation of menstruation should be viewed as malignant until proven otherwise.

Rate of Growth.—This is generally slow. It probably takes from eighteen months to two years for a tumor to attain the size of an orange, but the rate varies so widely with the different conditions that no rule can be established. In general, myomata grow more rapidly in young women. Pregnancy also accelerates the growth. During pregnancy, and especially from the third month on, the growth is frequently rapid. Marked edema is prone to develop during pregnancy and, by increasing the volume of a tumor, may simulate rapid growth. The actual growth is, however, often markedly accelerated during pregnancy. The tumors often shrink during the post-partum period, but rarely to their former size. The approaching menopause usually causes a retardation and, after its establishment, cessation of the tumor growth. In this connection it must, however, be borne in mind that the menopause often is delayed in myoma patients, and it is not uncommon to find them menstruating more or less regularly at fifty or more

years of age. Furthermore, the time consumed by the change in these women is longer than normal.

It is, therefore, unwise to delay the treatment of a patient forty-five years of age or even fifty, in whom a myoma is producing symptoms, in the hope that the menopause will be established.

After the establishment of the menopause myomata undergo shrinkage, but rarely disappear entirely unless they have been small and are usually palpable as firm fibrous nodules. The relative amount of fibrous and muscular tissue varies quite markedly in these tumors, and it is probably that those containing the greatest proportion of muscular tissue undergo the greatest shrinkage.

As has already been stated, it may be regarded as a rule that myomata do not develop or continue to grow after the establishment of the menopause, and the same is true after a bilateral oöphorectomy. Frank [3] has, however, collected reports of a number of cases from the literature in which the disease followed castration. Gibson [13] observed the appearance and growth of a myoma after castration, which tumor reached the size of a child's head in seven months time. Müller [14] states that 0.9 per cent begin after the menopause, and Hofmeri,[15] Leo,[16] Doler,[17] and Küstner [18] have reported such instances.

Supposed myomata developing after the meno-

pause should be viewed with suspicion, as sarcoma is much more common at this period. Those which develop long after a double oöphorectomy may be due to the fact that the oöphorectomy has not been complete.

The degenerative changes which so commonly affect fibromyomata rarely occur after the menopause is definitely established. Degeneration is especially likely to occur during the later months of pregnancy and during the puerperium, and probably often results from the pressure and alteration in blood-supply which the tumors suffer under these conditions.

Fibromyomata of the uterus may be cervical or fundal. Lockyer [19] states that 8 per cent are cervical, but our findings give a much lower figure.

The fundal tumors are divided into (1) the intramural or intramuscular or interstitial, (2) The submucous, (3) the subperitoneal or subserous, and (4) the subperitoneal pedunculated. All myomata are intramural in their early stages. Occasionally a tumor develops between the layers of the broad ligament—the intraligamentous or retroperitoneal type. Both the subperitoneal pedunculated and, more rarely, the intraligamentous may become entirely separated from the uterus, and then derive their blood-supply through adhesions to the intestines, omentum, or vessels in the broad ligament.

These tumors are termed parasitic, migratory, or wandering myomata.

Occasionally, pedunculated submucous tumors become separated from their point of attachment, and in this manner a spontaneous cure may in rare

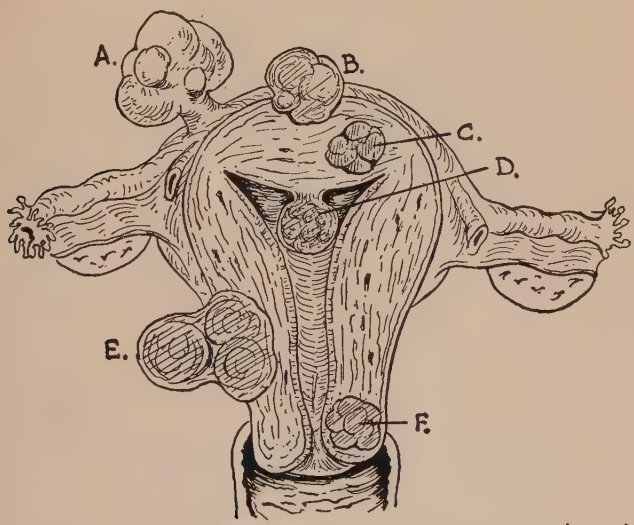

FIG. 10.—*Diagram showing the common varieties of uterine myomata.* A—Subperitoneal pedunculated. B—Subperitoneal. C—Intramural. D—Submucous. E—Intraligamentous. F—Cervical.

instances be effected. Calcereous submucous myomata were termed "womb stones" by the older writers. Myomata may originate in the ligaments of the uterus, most frequently in the round ligament, and in rare instances may spring from the recto-

vaginal space. Adenomyomata are more common in the latter region than are fibromyoma.

On section, myomata are seen to be composed of hard white fibrous tissue, arranged in irregular whorls, which are small in some tumors while large in others. The tumor substance is much harder than the capsule and surrounding myometrium. The capsule retracts on section, and the neoplasm stands out from the surrounding tissue. The myometrium forms this capsule, which contains the blood-supply of the tumor.

Myomata are rather avascular tumors, which is especially noticeable toward the center of a neoplasm. The blood-supply of these tumors, and the mechanism of the hemorrhage which they are prone to produce, have been carefully studied by the late John G. Clark.[20] He showed that when the nodules are small the blood-vessels surrounding them are correspondingly small, but that when the tumors are large, very large vessels pass through the muscle and ramify over the surface of the myoma. Two definite vascular systems may be demonstrated, one supplying the muscle and the other forming a network over the tumor. In cases of large myomatous uteri, the uterine and ovarian vessels are often enormously increased in size, and are probably a causative factor in the occurrence of

postoperative thrombosis and embolism which occasionally occur. Sampson [21] also studied the blood-supply of myomata, and found that most tumors

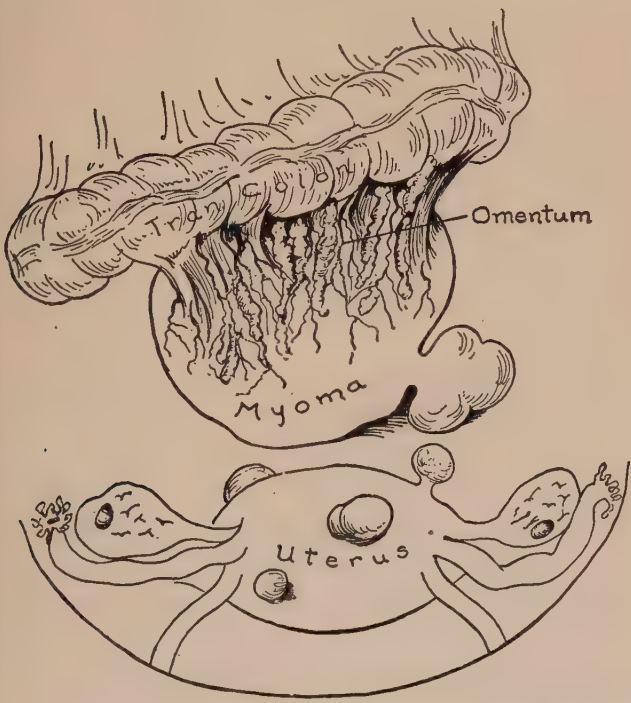

FIG. 11.—*Parasitic or wandering uterine myoma.* The largest tumor has become separated from the uterus and derives its blood-supply from the omental and other adhesions.

possessed one main artery and a rather scanty venous system.

Myomata are generally multiple, various types

and sizes being present. The submucous variety is more likely to be single than is any other. On account of their location and of the frequent interference with their blood-supply, submucous tumors are more subject to degeneration, sloughing, gangrene, and infection than are the other varieties. The endometrium is often stretched and thinned over the dome of the tumor. The endometrium of the uterine cavity itself is often also thinned, and shows the results of pressure. These tumors frequently lead to marked distortion of the endometrial cavity, and may fit cup-and-ball like into the latter.

The presence of the tumor promotes uterine contractions, which tend to force the myoma through the cervix. In this manner long pedicles may be produced, and the neoplasm may occasionally be found presenting at the vulva cleft or even entirely outside of the body. The cervix in these cases sometimes exhibits remarkable thinning as a result of pressure.

Multiple submucous tumors are sometimes faceted. Intramural tumors may produce marked elongation of the endometrial cavity. Subperitoneal tumors are especially prone to grow to great size. The parasitic or wandering myomata are especially likely to undergo degenerative changes, resulting from inadequate blood-supply.

In the pathological laboratory of the Department of Obstetrics and Gynecology at the University of Pennsylvania there are 1,868 specimens of fibromyoma of the uterus which have been removed by operation. Their situation and the proportion undergoing gross degenerative change follows:

	Number of specimens	Benign macroscopic degeneration	
		Number	Percentage
Subperitoneal	682	161	23.6
Mixed	437	85	19.4
Intramural	358	49	13.6
Submucous	228	25	10.9
Intraligamentous	100	16	16
Subperitoneal pedunculated	57	20	35
Parasitic	6	2	33.3
Total	1868	358	

During the period in which these tumors were removed, 111 adenomyomata and 88 sarcomata were operated upon. Forty-four of the latter had evidently developed in myomata (sarcomatous change). In addition to the above list, there were seventeen fibromyomata, one adenomyoma, and five sarcomata which sprang from the cervix. It will be noted that myomata are nearly 3.5 times more likely to grow outward toward the peritoneum, than to grow inward toward the endometrium. The subperitoneal variety is the most frequent, constituting nearly one-third of all the cases. About 58 per cent of the tumors showed degenerative changes upon histologic examination, but, as most of these were of

no clinical significance, only those exhibiting gross changes have been classified as degenerated in the above list.

In the majority of myomata an area of degeneration can be demonstrated by histologic examination, but, unless detectable by the naked eye, most of the changes are of no clinical significance. An exception to this is the sarcomatous change, which is of greatest importance. This is, however, not a true degeneration.

The following table shows the proportion of sarcomata among solid uterine tumors:

Fibromyoma of the body of the uterus	1,868	2,067
Adenomyoma of the body of the uterus	111	
Sarcoma of the body of the uterus	88	
Fibromyoma of the cervix	17	
Adenomyoma of the cervix	1	
Sarcoma of the cervix	5	
	2,090	

Of the 2,067 solid tumors occurring in the body of the uterus, 88 were sarcomata. Forty-four of these were apparently sarcomatous from the beginning, while the remainder had developed from myomata (sarcomatous change). In other words, in this series myomata were twenty-two times more frequent than sarcomata, and the former underwent sarcomatous change in 2.3 per cent of cases.

Malignant Change in Fibromyomata of the Uterus.—This is of rare occurrence. As the name implies, the fibromyomata contain only fibrous and

muscular tissue, and malignant neoplasm occurring in them must necessarily consist of the same elements—*i.e.*, they must be either sarcoma, endothelioma, or perithelioma. The occurrence of the two last mentioned is questionable. Adenocarcinoma may develop in the endometrium covering a submucous myoma, or from the endometrial like structures of an adenomyoma. The latter type of development is analogous to that of a fundus carcinoma occurring in a myomatous uterus, which is not a true degeneration or change of a fibromyoma.

According to Kelly and Cullen,[1] Virchow [22] gave a clear account of the gross and histologic picture in 1863. In 1872, Chrobak [23] again drew attention to this condition and, in 1887, Ritter [24] published a critical review of the subject and abstracted the existing literature to that date. Of especial historic value are the papers of Williams,[25] Schreher,[26] Pick,[27] and Gessner.[28]

Frequency.—Some of the older writers placed the incidence of sarcomatous change as high as 10 per cent. This can probably be accounted for by a lack of experienced pathologists. The great majority of myomata, in the process of benign degeneration, show some extremely cellular areas which, no doubt, have frequently been mistaken for sarcoma. The term "sarcomatous degeneration" is itself open to criticism, "sarcomatous change" being the correct

name for the process in question. Sarcoma represents a multiplication of cells, which is quite the antithesis to a degeneration. However, the former term is so generally used that an attempt at correction of terminology would be useless at the present time. For further reference to this subject see the chapter on "Sarcoma of the Uterus."

The myomatous uterus generally contains a number of tumors. Half a dozen or a dozen growths are most often found, but as many as seventy-five or more have in some cases been observed in a single uterus. The size of the individual tumors varies, some growths being microscopic, while others are immense and practically fill the peritoneal cavity. Hunter [29] relates the case of an enormous tumor which weighed 140 pounds, and McDonald [30] reports one of 90 pounds. As a result of improved diagnostic and operative facilities, the enormous tumors, so common in the past, are rarely met with today.

Myomata generally produce an irregular, hard, nodular lesion, which may simulate a displaced liver, spleen, kidney, or other organ, or may resemble a pregnant uterus. Remarkable mimicries are sometimes observed.

Histologic examination shows a tumor of simple structure, composed of interlacing bundles of unstriped muscle and fibrous tissue. The muscle tissue

may run in any direction, but often presents a circular arrangement, especially in young tumors. In very small tumors the amount of fibrous tissue is often extremely small. The muscle-cells are spindle-shaped and the nuclei are narrow. Nuclear figures are rare.

The edges of the tumor are sharply differentiated from the myometrium, generally by an even line of demarcation. Occasionally the myoma may grow outward in an irregular manner. The muscle-cells may be closely aggregated or far apart but, in any event, they are evenly spaced and the cells and nuclei are regularly arranged and of fairly equal size. Irregularity of size, shape, and staining properties of the cells or nuclei; giant cells, mitosis, or many nuclear figures; penetration of the capsule, and absence of intercellular stroma—all these conditions suggest a sarcomatous change. The majority of myomata exhibit hyaline degeneration, and edema and cystic degeneration are common. Red or carneous degeneration is not infrequent, and is said to be more common following pregnancy. Calcareous degeneration may occur as a shell-like deposit around the periphery of the tumor, or in isolated areas of varying size throughout the substance of the neoplasm. This form of degeneration is particularly likely to take place in old subperitoneal pedunculated and parasitic tumors, although

it may be present in any variety. Angiomatous, mucoid, myxomatous, fatty, and other degenerations may occur. Edema is to be differentiated from lymphangiectasis. In the latter the cavities are lined with endothelium.

Changes in the Myometrium Associated with Myoma.—The myometrium is prone to be hypertrophied, sometimes three or more times thicker than normal. This is less evident in the case of small tumors, but is often marked even in medium-sized growths. Hypertrophy of the myometrium is usually present with the intramural types of myoma, edema of the myometrium occasionally occurs, and partial hyaline degeneration has been observed. The blood-vessels are enlarged and, in some specimens, the myometrium is extremely vascular. Arterial sclerosis has been observed.[1, 20, 21]

Changes in the Endometrium.—The endometrium may be normal, but pressure changes are of common occurrence, especially when submucous tumors are present. The mucosa is generally thickened around the base of such a tumor, while it may be drawn out and much thinned over the dome of the growth. Only in rare instances is there a loss of continuity of the investing endometrium.

As the result of pressure the endometrium is often flattened, the surface smooth, and the course of the endometrial glands is altered; indeed, in cer-

tain areas it may follow the long axis of the uterus. The surface epithelium may be flattened or occasionally desquamated, and the stroma condensed. In about 9 per cent of specimens hyperplasia is present. This condition was first described by Cullen in 1900, and has later been studied by Meyer,[31] Schröder,[32] Novak and Martzloff,[33] and many others.

The term "hyperplasia" is often applied somewhat loosely, but, as defined by Cullen, it refers to a condition of the endometrium which produces a characteristic histologic picture. The endometrium is generally thickened, and may be two cm. or more in depth; less frequently it is thinner than normal. The chief feature is the presence of large glands. These are round or oval, their lumen is smooth and lined by a single layer of columnar epithelium. In some specimens the enlarged glands are closely aggregated, while in others only isolated glands are present. The arrangement of these glands has given rise to the term "Swiss-cheese pattern." The stroma often exhibits condensation, and mitotic figures are frequent. Considerable thickening of the endometrium without the typical histologic hyperplastic changes, however, is often present in myomatous uteri, and endometrial polyps are frequently associated with this form of hypertrophy. In a previous chapter the association of carcinoma of the endo-

metrium and myomata has been referred to, and the fact pointed out that fundal cancer is probably slightly more frequent in myomatous than in non-myomatus uteri. Chronic endometritis is infrequent.

Condition of the Tubes.—It is not uncommon to find a Fallopian tube drawn out and elongated over an underlying tumor. The frequency of salpingitis varies markedly in different clinics. Salpingitis is more frequent in the colored race, as are also myomata. In some of the Southern clinics where a high proportion of the patients are negroes, the incidence of salpingitis accompanying myomatous uteri is nearly 90 per cent. In the gynecologic and obstetric laboratory of the University of Pennsylvania, salpingitis was present in about 30 per cent of cases submitted to operation. Almost 20 per cent of our myomata were treated by radium irradiation, and as this form of treatment is not employed when inflammations of the adnexa are present, this further reduces the incidence of inflammatory lesions of the tubes in our cases. In cases of large myomata the incidence of salpingitis is somewhat greater than with small tumors.

Condition of Ovaries.—When an inflammation of the tubes is present the ovaries are usually also involved. Various grades and types of oöphoritis may be present. Apart from inflammatory changes, true hypertrophy of the ovary is not infrequent and

may be so marked as to render the organ four or five times larger than normal. Such an ovary is perfectly normal except for its size. The overgrowth is not necessarily due to edema, although edema may be present in association with a myoma. It is probable that the hypertrophy of the ovaries and endometrium, and even the development of the myomata, may be all due to some primary ovarian derangement.

Endometriomata, endometriosis, perforating hemorrhagic cysts, adenoma ovarii endometrioides, menstruating cysts, chocolate cysts, or Sampson's cysts are of common occurrence. They are small or medium-sized, often multiple, occurring most commonly in the ovary. They contain blood, and are lined by endometrial-like tissue which often is considerably altered as the result of pressure. They are not present before puberty, and are most common in ages between thirty and fifty years.

Sampson [34] believes them to be due to a regurgitation of particles of desquamated endometrium and menstrual blood through the tubes. It is well known that a certain amount of desquamation of the surface endometrium occurs during menstruation, and that the menstrual blood contains particles of the tissue. These particles of endometrium "seed" upon the ovary and adjacent structures. In accordance with this theory, these tumors are very

commonly observed in patients in whom there is some obstruction in the lower uterine segment—such as an acute retroflexion or a myoma. Sampson has also shown that, in some instances, the escape of tissue elements takes place *via* the lymphatics.

In the laboratory of obstetrics and gynecology at the University of Pennsylvania, endometriomata have been found associated with myomata in 8 per cent of cases in which hysteromyomectomy and bilateral salpingo-oöphorectomy have been performed. In a typical case the tubes are patent, tortuous as a result of adhesions, and the ovaries contain one or more blood-filled cysts. The blood may be bright, tarry, or chocolate-like in appearance. Often the cyst shows evidence of a previous rupture, the scar being represented by a puckered cicatrix. The cysts vary from a few mm. to ten or more cm. in diameter, but are most often no larger than a grape. The ovaries are often slightly enlarged, and usually show adhesions. The ovaries, posterior wall of the broad ligament, and cul-de-sac are the most frequent sites for these lesions. Dysmenorrhea and pain incident to the adhesions are the chief clinical manifestations of endometrioma. These are often mild, and in many cases no symptoms are present or are masked by those of the myoma. In the older and larger lesions the lining membrane is often desquamated as a result of pres-

sure. It is usually in the small cyst of not more than a few millimeters in diameter that the most typical histologic characteristics are observed.

In 1921 Sampson related his observations regarding these lesions before the American Gynecological Society and, since that time, the subject has been extensively discussed in the literature, Sampson himself contributing no less than ten papers.

Symptoms.—Many of the uncomplicated myomata are symptomless, and this is especially true of the subperitoneal forms. Small or medium-sized intramural tumors are frequently silent, while submucous tumors may produce marked symptoms even when small. The symptoms depend largely upon the location of the tumor. The most frequent are bleeding, discharge, pressure symptoms, and sterility. Secondary signs—such as anemia, and toxemia due to absorption from degenerating tumors—are of common occurrence. Abortion, miscarriage, dystocia, and trouble during the puerperium may result if pregnancy occurs. Dysmenorrhea, omaphobia, neurasthenia, digestive disturbances, or constipation may be present.

Hemorrhage.—The bleeding is generally menorrhagic in type. It usually begins as an increase in the duration of the period, soon followed, or perhaps preceded, by an increase in the amount of flow.

The menorrhagia is of gradual onset, fairly regular periodicity often being maintained over a prolonged period. Finally, however, hemorrhages lasting ten to twenty or more days may erase all trace of regularity. In such a prolonged hemorrhage the flow is often profuse for the first few days, and may continue for weeks as a slight leakage, sometimes bright red but more often of a "prune-juice" color, with intervals of more active bleeding. The hemorrhage is augmented by physical activity, and tends to diminish on rest in bed. Any form of treatment short of irradiation or removal may, however, be powerless to definitely check the hemorrhage. During the period of active bleeding, clots are frequently passed. The intermenstrual period is shortened. The fact that the hemorrhage due to myomata is nearly always menorrhagic at the onset and slow in development is an important diagnostic feature. Fatal hemorrhages have been recorded, but are of extremely rare occurrence. These patients may bleed more or less profusely for weeks despite palliative treatment, and this often leads to a severe grade of anemia. The writer has, however, never seen a fatal hemorrhage, nor has such a case ever occurred in the gynecological service of the University Hospital during the last thirty years.

Submucous tumors are most prone to produce hemorrhage, and do so by exerting tension upon

the endometrium, the tumor acting mechanically as a foreign body. Another probable reason for hemorrhage is the ovarian malfunction which very likely is present. Enlargement of the uterine cavity is quite common, and may also be a contributing factor. In rare instances a submucous tumor may produce such tension that the endometrium may actually give way, and the tumor then protrude beyond the retracted mucosa. Secondary complications may also contribute to the hemorrhage.

The size of the uterus is no certain guide to the amount of menstrual disturbance. Small submucous tumors may result in marked hemorrhages, whereas large tumors—especially those of subperitoneal type—may cause little change in the menstrual cycle. The hemorrhage resulting from myomata is always venous.

Internal hemorrhages are of rare occurrence. Hemorrhages due to rupture of a blood-vessel, from torsion or gangrene, or to rupture of a large blood-vessel in an adherent omentum, have been recorded by Ransohoff and Dreyfoss.[53]

Anemia.—This may result from hemorrhage, or may be toxic in origin and due to absorption from a degenerated or infected tumor. In some cases, a combination of both these causes is responsible.

Extreme degrees of anemia are sometimes observed. The lowest hemoglobin content that the

writer has personally observed was 12 per cent. This occurred in a woman who had been suffering from menorrhagia for twenty-eight months, and in whom the hemorrhage had been almost continuous for the last two months prior to her admission to the hospital. Hemoglobin contents as low as 30 per cent are frequently observed. The accompanying signs and symptoms of anemia are present. Women are able to stand a surprisingly large amount of hemorrhage, apparently much more than men. Equally remarkable is the satisfactory response to treatment which is exhibited by these patients when the hemorrhage is checked.

An anemia secondary to toxemia rarely reaches the extreme grades which follow hemorrhage, but signs and symptoms of toxemia are always present.

The hemorrhage resulting from myomata is generally painless. If intrauterine clotting occurs, efforts of the uterus to expel the clots result in uterine spasm, and cause pain over the tumor. When a submucous myoma and marked distortion of the endometrial cavity is present, pain may also be present. With inflammatory lesions of the adnexa the pain is of a different type.

Discharge.—This generally manifests itself as a rather thin, unirritating, nonodorous leucorrhea, in rare cases requiring the constant application of a vulvar pad. The discharge varies with the case, and

is absent in some instances. When submucous tumors undergo degeneration, and especially in necrosis, a discharge is always present and is dark, malodorous, and may be blood-streaked. In no other type of gynecological disease—except neglected cases of carcinoma—is the discharge as malodorous as in extensive necrotic submucous myomata. The older writers believed that the odor was characteristic, although carcinoma may result in equal discomfort as far as this symptom is concerned. Pruritus of the vulva may result.

Pressure Symptoms.—These naturally vary with the size and position of the tumor. Myomatous uteri which appear molded into the pelvis, or in which the lower portions still remain in this position, are most prone to produce pressure symptoms. Vesical symptoms are frequent, and may result from actual pressure upon or distortion of the bladder as the latter is drawn upward by the enlarging tumor. Frequency and dysuria are common, and retention may occur. Pressure upon the ureters may result in hydroureter, or hydronephrosis, and other renal complications. Pressure upon the rectum may produce constipation, or difficult and painful defecation, and may be the result of actual pressure upon the bowel or of interference with normal peristalsis.

It is remarkable how few rectal symptoms actu-

ally are present even in those cases in which the myomatous uterus appears to fit into the pelvis in almost a ball-and-socket manner. Pressure, however, often results in hemorrhoids or in edema of the lower extremities. Pressure upon the sciatic nerve may cause pain along its course in the posterior portion of the thigh and leg. Large tumors may produce distortion and displacement of various viscera. A feeling of discomfort and weight in the pelvic region is common.

Toxemia.—Degeneration and absorption of tumor tissue may result in hyperpyrexia, nausea, vomiting, anemia, leucocytosis, headache, malaise, and loss of strength and weight. Anemia out of proportion to the amount of hemorrhage is generally due to this cause, even if softening of the tumor is not clinically demonstrable.

Sterility has previously been referred to.

Pain is relatively infrequent in small or medium-sized uncomplicated tumors and, when present, is usually due either to pressure or inflammatory lesion of the adnexa or to adhesion of the tumor to adjacent structures. Uncomplicated myomata are not in themselves tender or painful. Dysmenorrhea has already been referred to and, in the absence of distortion of the endometrial cavity, inflammatory lesions and intrauterine clotting is of rare occurrence. In this respect myomata differ from diffuse

adenomyomata, which are almost always accompanied by painful menstruation and premenstrual tenderness of the tumor. Gastro-intestinal disturbances, neurasthenia, omaphobia, and circulatory disturbances are among the less frequent developments.

Heart lesions are by no means uncommon. They are especially likely to accompany large tumors of long standing and, when well marked, secondary anemia is present. The so-called "myoma heart" is of this type. A compensatory dilatation of the heart may be present, but generally disappears after removal of the tumor. In neglected cases, loss of compensation may result. Heart lesions, unless incidental, are rarely of sufficient gravity to interfere with anesthesia, especially if properly administered ether is employed.

Torsion is one of the less frequent complications of myomata. Torsion may result from a twist of a pedunculated myoma, or the entire uterus may be involved. The softening of the lower uterine segment in pregnancy apparently favors the latter accident. As in the more common torsion of ovarian neoplasms, the symptoms may be either acute and fulminating, or more or less chronic. Minor degrees of torsion are by no means uncommon, but acute torsions are rare. Instances have been recorded in which complete avulsion has occurred. Gangrene

and peritonitis rapidly follow the acute type, which is generally mistaken for torsion of an ovarian cyst.

In 1909 Piquand and Limeland collected 84 cases of torsion from the literature, 14 of which were associated with pregnancy. Seventeen years later Hitzanides found 85 recorded cases, and Peightal relates 49 additional cases in a recent careful review.

The etiological factors in torsion of myomata are the same as in torsion of ovarian tumors—*e.g.*, the development of a pedicle, an irregular-shaped tumor pushing upward past the promontory of the sacrum, peristaltic action of the intestines, etc. The dextro-rotation of pregnancy, and the fact that the right lumbosacral fossa is less full than the left, have also been suggested as causative factors. In cases where torsion occurs, adhesion to the intestines is frequently present.

The prognosis depends upon the degree of torsion and, in the acute form, the promptness of operative intervention. Piquand reported a mortality of 75 per cent among cases in which operation was not performed. For an exhaustive review of torsion, the reader is referred to the excellent studies of Peightal,[36] Piquand and Limeland,[37] and Hitzanides.[38]

Myomata and Pregnancy.—Despite the fact that myomata are prone to develop in nulliparous and

sterile uteri, the association with pregnancy is rather frequent. One-child sterility is common in these cases. Of 1,997 specimens of myomata observed by the author, 46 were associated with pregnancy. This does not represent the incidence of pregnancy with myoma, but the proportion requiring operative intervention during pregnancy. The combined statistics of Hofmeier,[39] Scipiades,[40] Peham,[41] Kelly and Cullen [1] comprise 3,776 cases of uterine myomata, 154 of which were associated with pregnancy. Combining these observations with those of the author, we find that 200 pregnancies occurred in 5,773 myomatous uteri—*i.e.*, a proportion of one pregnancy to every 28.5 cases of myoma. As has already been stated, pregnancy is prone to cause changes in the tumor, and the presence of the tumor may result in abortion, miscarriage, or dystocia.

If pregnancy occurs, the rate of growth of the tumor usually increases, especially after the third month. Edema is prone to develop, and adds to the bulk of the tumor. Due to pressure and changes in the vascular supply of the tumor, the various degenerative changes are more likely to take place. Carneous or red degeneration, necrosis, and suppuration are among the most common degenerations productive of serious complications. Even if labor is successfully accomplished, the pressure and trauma incident to it may lead to necrosis or other

change which may then become manifest during the puerperium. Much depends upon the size and situation of the tumor.

Lockyer [19] quotes the following statistics bearing upon sterility:

Goetze [42] found that in 50 per cent of the sterile cases growths the size of a man's head or larger were present. His statistics also showed that 91 per cent of women with submucous myomata had borne children, and that this type of tumor was more common in married than in single women.

Lynch and Maxwell [8] found that 80 per cent of the submucous tumors occurred in multiparæ. It would, therefore, appear that the single submucous variety of myoma is less likely to be preceded by sterility than are the other forms.

Lockyer furthermore quotes Wilson as stating that 50 per cent of patients with submucous myoma had five or more pregnancies.[43]

If the uterine cavity is markedly distorted, as by the presence of a submucous tumor, sterility is the rule. If the pressure and distortion are only moderately marked, abortion or miscarriage is likely to occur, and, if the uterine cavity is normal but the tumor situated low on the uterine wall, dystocia or actual blockage of the birth canal may result. Subperitoneal myomata situated at the fundus may not markedly interfere with either pregnancy, labor,

or puerperium. Cervical myomata are especially likely to cause dystocia.

The softening of myomata frequently leads to spontaneous delivery in cases which, prior to the onset of labor, apparently presented insurmountable difficulties. This subject has recently been reviewed by Polak in an authoritative paper.[44]

Diagnosis.—The diagnosis of a uterine myoma is usually not difficult, unless the patient is stout or the case is atypical. The age of the patient, the tendency of the tumor to develop in nulliparæ and in the colored race, the gradual evolution of symptoms, the slow growth, the development of menorrhagia and its secondary symptoms, the discharge and pressure symptoms, and the presence of a hard, irregular, nodular pelvic neoplasm of uterine origin, generally make the diagnosis easy.

When any intraperitoneal tumor is discovered, its point of origin should be determined. All intraperitoneal tumors tend to migrate to the center of the abdomen, and this is particularly true of the larger new-growths. Renal, hepatic, and splenic tumors are prone to extend downward, and pelvic neoplasms upward. It is usually an easy matter to determine whether the tumor has originated in the upper abdomen or in the pelvis, and in the latter case the point of origin is probably in the ovary or

uterus. Uterine myomata and ovarian neoplasms are the two most common pelvic tumors reaching the size of an orange or more. The former are seven times as frequent as the latter. Of ovarian neoplasms, cystic tumors are thirteen times more frequent than are solid new growths.

The following physical signs are of importance in determining whether the tumor is uterine or ovarian in origin:

Uterine Tumors	*Ovarian Tumors*
1. Tumor moves with the cervix. If a tenaculum is attached to the cervix and the cervix pulled down, and the tumor then pushed upward, this point can generally be readily demonstrated. A pedunculated uterine tumor may, however, give negative result. Occasionally the uterus is so firmly fixed by adhesions, or so molded into the pelvis, that this test is rendered useless.	1. Ovarian tumors generally possess pedicles of considerable length, and the cervix does not move at all or moves very little in the tenaculum test. Occasionally an ovarian tumor may be adherent to the uterus, and if this is the case the tumor will move with the cervix.
2. The uterus cannot be palpated as a separate organ. A pedunculated tumor may nullify the value of this test.	2. It may be possible to palpate the uterus as a separate structure.
3. Tumors are generally multiple and of varying size.	3. Tumor generally single, although bilateral neoplasms may be present.
4. Tumor usually hard. Degeneration may cause softening, and extensive cystic change may result in evident fluctuation.	4. Tumor often cystic, and fluctuation may be elicited. Solid tumors, as well as cysts composed of small loculi, may seem hard upon palpation.
5. Tumor is irregular, and asymmetrical in situation.	5. Generally single, round or oval and, because of its pedicle, situated in or near the midline.

In passing, reference may be made to the John G. Clark trimanual method of eliciting fluctuation. This method is especially valuable in the case of small or medium-sized tumors and is performed as follows: The ordinary bimanual examination is performed, and the tumor palpated in the usual manner between the fingers in the vagina and those upon the surface of the abdomen. The fingers of the operator which are upon the abdominal wall are then percussed by an assistant. If the tumor contains fluid, the fluctuation wave is transmitted to the fingers within the vagina. This is an extremely delicate test, and with its use small collections of fluid can usually be easily detected.

The differential diagnosis between myomata and pregnancy may be difficult. Even after the abdomen is opened, some doubt may still exist. A single softened myoma is especially likely to simulate pregnancy. If the abdomen has been opened, the situation of the uterine ligaments almost definitely indicates the condition. The round ligaments are especially prone to be asymmetrical and abnormal in location in the case of a tumor. In cases of doubt, the history and physical signs will usually clear this point and, if uncertainty still exists and if the condition of the individual case permits delay, the time test should be employed. A delay of a few weeks, or at most a month or two, will render a definite

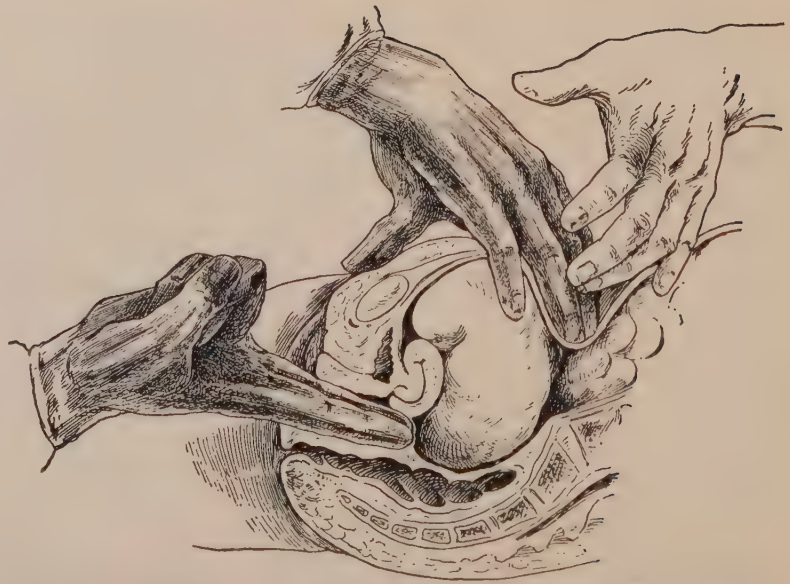

FIG. 12.—*The John G. Clark trimanual method of eliciting fluctuation.* This method is of value in differentiating cystic from solid pelvic tumors.

diagnosis possible. In the average doubtful case it is better to wait a short time than to run the risk of instituting radium or other radical treatment in a patient who may be normally pregnant.

In the case of pregnancy occurring in a myomatous uterus, the diagnosis is more often confused. Here the history and the signs of pregnancy add to the difficulties. Generally, the presence of the tumors and the irregular shape of the uterus make the recognition of the former easy, but in cases where the history is atypical or concealed or where abortion occurs, especially in a stout patient, difficulties are prone to arise.

Diagnostic X-ray may be advisable under exceptional circumstances. Calcareous myomata show up plainly in Roentgen pictures, while uncomplicated myomata may be faintly distinguishable. By this means the presence of a fetus can be positively determined after the fifth month of pregnancy, and can usually be demonstrated somewhat earlier. Murphy [45] has shown the danger of therapeutic application of the X-ray in pregnancy. Heavy irradiation by the X-ray may result in various fetal deformities, especially microcephaly. It is probable that the lighter X-ray dose required for a picture is harmless, but this point has not yet been determined. Its application, combined with the lipiodol injection into the uterine cavity, may be of value in

rare instances. The diagnosis in doubtful cases can, however, usually be made without the use of X-rays. The rapid increase in size of a myoma, incident to pregnancy or the presence of a uterus bicornus, may further complicate the diagnosis.

In general, the larger the myoma, the easier is its recognition. Small myomata may be mistaken for adnexal lesions, and large or medium-sized tumors may be confused with retroperitoneal new-growths. For the differentiation of the latter the history of the case is of distinct value. Retroperitoneal tumors are often sarcomata and are therefore more rapid in growth than are the myomata. They also may develop and grow after the menopause. In the case of the retroperitoneal growth, it is generally possible to palpate the uterus as a structure separate from the tumor. In some cases the use of the uterine sound is a valuable diagnostic aid. It is needless to state that the sound should not be employed if pregnancy is suspected, and that it should be used only under the strictest aseptic conditions. Pneumoperitoneum, as suggested by Peterson and others, is a valuable procedure in differentiating between intra- and retroperitoneal tumors.

As previously indicated, myomata may produce remarkable mimicry of the intraperitoneal organs. Tumors almost identical with the kidney in size and

shape have been frequently recorded. On the other hand, the author has observed a congenitally misplaced kidney which was at first mistaken for a uterine myoma. Ureteral catheterization combined with the X-ray will aid the diagnosis in such cases.

An adenomyoma of the circumscribed variety cannot be differentiated from an ordinary myoma before the removal of the tumor. As the treatment is similar, this point is of no practical importance. The diffuse variety of adenomyoma constitutes a small or medium-sized tumor, rarely larger than a uterus in the third month of pregnancy. The tumor is moderately symmetrical. The adnexa generally show adhesions, and the ovaries are often the seat of small cysts. There is a history of dysmenorrhea beginning shortly before the flow. During the premenstrual and early menstrual period the uterus becomes slightly larger and more tense, and is often quite tender.

Treatment.—Some myomata only require observation, others are preferably treated by irradiation, and still others should be treated by removal.

Symptomless, slowly growing, or stationary myomata should be kept under observation. The patient should, generally, be informed that a benign tumor is present which may always remain innocuous or may require treatment at a later date. In any event, a responsible member of the patient's family should

be told of the condition. Under no circumstances should the physician alone assume the responsibility.

The patient should be examined at monthly intervals for three or four months, in order to determine the rate of growth. If, at the end of three or four months, it is apparent that the tumor is stationary and not increasing in size, the period between the examinations may be lengthened to three months and the patient advised to return immediately should symptoms develop. At each examination, notations should be made regarding the size of the tumor and the presence or absence of symptoms. The older the patient, the better is the chance of avoiding active treatment. In young patients the removal of the tumor is sometimes indicated if pregnancy is expected, or if the patient is so situated that adequate treatment will not be available in the future. Occasionally omaphobia may be so pronounced as to make removal of the tumor necessary. In case of doubt, it is generally best to state the situation to the patient or some responsible member of the family, and allow him or her to make the choice between observation and active treatment. In general, small symptomless tumors should be kept under observation, and active treatment avoided. Many cases belong to this group. Rapid growth is an indication for immediate removal.

Indications for Irradiation.—Small, uncomplicated, non-pedunculated tumors, causing bleeding in women of forty years of age or over, are the most suitable for irradiation. Pulmonary tuberculosis and other grave contra-indications to operation also make irradiation the treatment of choice. In properly selected cases the irradiation leads to a high proportion of permanent cures, is associated with practically no mortality, and, in the small proportion in which a permanent cure is not effected, in no way hinders a subsequent successful removal of the neoplasm. The indications and contra-indications to this form of treatment will be better understood if we consider the limitations of irradiation. Irradiation may be expected to check uterine bleeding resulting from myomata in nearly all cases, provided an adequate dosage is employed. In the majority of the cases it effects a shrinkage of the tumor.

Gauss and Friedrich [46] observed shrinkage or disappearance of the tumor in 70 to 80 per cent of cases. Polak [47] secured shrinkage to half the original size of the tumor in 80 cases, and absolute disappearance in 20 of these, in a series of 106 cases —*i.e.*, shrinkage or disappearance in about 75 per cent. In a series of large myomata, Burnam [48] found a shrinkage in half the number of cases. In the Gynecologic Division of the Department of Ob-

stetrics and Gynecology at the Hospital of the University of Pennsylvania considerable shrinkage or disappearance of the tumor occurred in 65 per cent of cases, in from six months to one year.

Intramural tumors are most likely to undergo shrinkage, while the pedunculated subperitoneal variety is least affected. Complete disappearance of the tumor as far as palpable findings are concerned will occur in about one-third to one-half the cases. Shrinkage of the tumor is rarely detectable for three or four months or even longer, and in some cases is never noticeable. Tumor growth ceases almost at once upon irradiation. Tumor growth is dependent upon ovarian stimulation, and irradiation checks this and acts as would a bilateral oöphorectomy.

In a previous work [49] the action of irradiation in these cases has been discussed in detail. It will here suffice to mention the different theories as to the action of the irradiation: (a) the follicle-bearing constituents are destroyed; (b) an endoarteritis of the blood-vessels of the tumor and myometrium is produced; (c) an increase in the fibrous tissue of the myoma and myometrium is effected; and (d) the endometrium is affected and the production of cicatricial tissue is stimulated. Because of the development of all the symptoms of the menopause after irradiation, the histologic examination of

ovaries which have been submitted to irradiation, the fact that myomata cease to develop after the menopause, and the pathologic examination of myomatous uteri which have been submitted to irradiation, I place greatest credence in the theory of internal castration, although obliterative changes in the blood-vessels of the tumor and myometrium is probably also a contributing factor.

With these facts in mind, the following contra-indications to irradiation are readily appreciated.

CONTRA-INDICATIONS TO IRRADIATION

1. Doubt as to the accuracy of diagnosis.
2. Presence of intraperitoneal lesions, other than the myoma, which require surgical intervention.
3. Rapid growth of the tumor.
4. Associated pregnancy.
5. Associated neoplasms, such as fundal carcinoma or ovarian tumor.
6. Pressure symptoms.
7. Softening or degeneration of the tumor.
8. Inflammatory lesions within the pelvis, especially of the adnexa.
9. A myomatous uterus larger than a four-months pregnancy.
10. Submucous tumors, especially if pedunculated.
11. Young patients.
12. Marked anemia, out of proportion to the amount of

blood lost, especially when associated with other evidence of toxemia.

13. Obstructing tumors, or malformations which prevent the proper application of the radium.
14. Single pedunculated subperitoneal myoma.
15. Cervical myoma.
16. Radiophobia.

Accurate diagnosis is essential if irradiation is to be employed. Mistakes in diagnosis are likely to be followed by disastrous consequences. It is far safer to operate than to irradiate, unless the diagnosis is definite. This is one of the reasons why irradiation for pelvic conditions should be given only by those skilled in gynecologic diagnosis. The average X-ray expert is incompetent in this respect. Anesthesia, preferably by ether, may aid in clearing up a doubtful diagnosis.

On one occasion, the author made a small exploratory incision for the purpose of verifying the diagnosis in an extremely stout patient. A small uncomplicated myoma was found, the abdomen was closed, and irradiation employed. This is an exceptional case, but is quoted in order to emphasize the importance of accuracy in diagnosis.

The presence of other intraperitoneal lesions may be either indicative or contra-indicative to the employment of radium. In general, if the associated lesion makes it necessary to open the abdomen, the

myoma is best removed at the same time. However, a prolonged operation upon the gall-bladder or stomach may in itself be an indication for the shorter or less shock-producing procedure.

Myomata are slowly growing. Rapid increase in size of a tumor suggests malignancy or sarcomatous change. In either event, operative intervention is indicated.

Pregnancy constitutes an absolute contra-indication to both X-ray and radium therapy. If the irradiation does not cause abortion, injury to the fetus is likely to occur. In certain cases therapeutic abortion might be necessary, and irradiation of the tumor employed after recovery from evacuation of the uterus. A myoma associated with pregnancy in a tuberculous patient is an example of this.

As has already been stated, removal is generally preferable to irradiation in instances where the abdomen must be opened for some associated condition. This would certainly be the case when a carcinoma of the fundus or an ovarian cyst is present. On the other hand, if it were necessary to perform a partial gastrectomy for carcinoma in a patient who also had a uterine myoma which was causing bleeding, but which on account of its size would ordinarily be treated by removal, the gravity of the gastric operation would be an indication for irradiation.

Pressure symptoms are prone to develop when large tumors are present, and in such cases removal is better than irradiation, being quicker and more certain. Appreciable shrinkage of the tumor is noticeable six months after irradiation in about 65 to 75 per cent of cases.

Many of the degenerations—and practically all those that are likely to give rise to toxic symptoms—also produce softening of the tumor, although this softening may not be recognizable on account of the situation of the neoplasm. Minor degrees of degeneration are of frequent occurrence and no doubt often escape recognition and are successfully treated by irradiation. When the degenerative changes have reached a stage where it can be readily recognized by clinical methods, irradiation is contraindicated. Advanced degenerative changes often produce more or less marked toxemia, as indicated by fever, leucocytosis, anemia, and loss of weight, strength, and appetite. Irradiation does not check the degeneration, and, furthermore, its action is too slow and may aggravate the condition.

Adnexitis is a most common intraperitoneal pelvic inflammatory lesion. Polak [47] found salpingo-oöphoritis in 54 per cent of his cases, Kelly and Cullen [1] in 35.6 per cent, McDonald [12] in 27.5 per cent, and Frank [3] in 18 per cent. In those clinics in which the clientele consists largely of negroes, the

proportion of myomata which are associated with inflammatory lesions of the adnexa is often as large as 90 per cent. In these cases irradiation is contraindicated, because it is likely to cause an exacerbation of the infection. In many instances the infection causes more suffering than does the tumor. Irradiation as applied for bleeding is not bactericidal, and even if the myomata were eliminated the patient would still suffer from the inflammation.

There are many reasons to believe that irradiation and curettage do not always produce an exacerbation. Mild inflammations are not always recognized. Encapsulation tends to sterilize many adnexal lesions, and it is probably that irradiation is harmful only in those in which virulent microorganisms are present. Prior to operation there is, however, no way of determining this point with certainty, and it is safest to refrain from employing irradiation in all cases in which salpingitis is suspected. In the Gynecological Service of the Department of Obstetrics and Gynecology at the University Hospital, irradiation is refused in every instance where adnexitis is palpable or where the history indicates its presence. A history of gonorrhea or of a previous attack of pelvic peritonitis, pain which cannot be otherwise accounted for, leucocytosis, and fever or other evidence of inflamma-

tory complication in the adnexa are viewed as positive contra-indications to irradiation.

In tumors larger than a four-months pregnancy the ovaries are likely to be pushed far away from the uterine cavity and are, therefore, less certainly within the effective zone of irradiation. Furthermore, complications and pressure symptoms are more prone to be present. Burnam [48] has recorded satisfactory results of irradiation in 30 cases of large myomata, and the author has often successfully employed this treatment in very large tumors. When contra-indications to removal are present—*e.g.*, grave cardiac, renal, or pulmonary conditions—irradiation is in many cases the treatment of choice. Under such circumstances somewhat larger dosages of radium are required, and it is often advisable to follow it with X-ray therapy. Hemorrhage can usually be checked even in large tumors, but relief of pressure symptoms is slow and uncertain.

When more than half the tumor presents within the endometrial cavity, and especially if it is pedunculated, removal of the tumor is preferable to irradiation. Pedunculated tumors can generally be easily removed by vaginal myomectomy. This variety is more likely to be single than any of the others, and is also especially prone to infection and degenerative changes due to interference with its blood-supply. When a pedunculated submucous

tumor is present in a myomatous uterus which is otherwise suitable for irradiation, a vaginal myomectomy may be performed and radium applied three or four weeks later.

Myomata in young women are generally best treated by removal, and preferably by myomectomy. It is necessary to permanently inhibit the function of the ovary to secure definite results by irradiation, and this brings on the artificial menopause with its accompanying discomforts. It is generally preferable to remove the tumor, even if this necessitates a supravaginal hysteromyomectomy, rather than to apply irradiation. In most of these cases—even if it is necessary to remove the body of the uterus—the adnexa can be spared and the deleterious results of the menopause avoided or delayed. In some instances the amputation can be performed at such a high level that considerable endometrium may be preserved and menstruation continued. Occasionally, when pronounced contraindications to removal of the tumor exist, small doses of 400 to 600 mg.h. of radium may be employed, but the results of this form of treatment are less certain and recurrences more likely to occur. Temporary amenorrhea, varying from three to six months, may often be secured. The ovaries of young women are less susceptible to the effects of radium, and show greater regenerative power

than do those of older patients, therefore permanent sterilization is not likely to result from the employment of the above-named dose. If an operation is required later on, its success is not interfered with. Irradiation is associated with almost no mortality.

Anemia due to hemorrhage is a distinct indication for irradiation rather than removal of the tumor, as such patients are poor operative risks. Anemia out of proportion to the hemorrhage is an indication of toxemia, often due to absorption from a degenerated tumor, and should be treated by myomectomy or hysteromyomectomy, as has already been stated. Many such cases are associated with evening fever, leucocytosis, loss of strength and weight, and other evidences of absorption and softening of the tumor.

Obstructing tumors, and tumors associated with malformations which prevent the proper application of the radium or curettage of the entire uterine cavity, are obviously contra-indicative to irradiation.

Cervical myomata do not respond well to irradiation, and are usually most satisfactorily treated by removal.

Excessive fear of treatment by radium may occasionally make it advisable to employ other methods. The popular belief that radium is used only for carcinoma largely accounts for these rare

instances. In our clinic but one such case has been observed. If pronounced radiophobia is encountered in a case otherwise suitable for irradiation, curettage should be performed, the curettings examined histologically and, if no malignancy is encountered, the case treated by X-ray.

The contra-indications to irradiation should be received as general principles, and not as hard-and-fast rules.

Practically the same results can be secured with X-ray as with radium. X-ray irradiation of myomata should always be preceded by curettage and histologic examination of the endometrium, because:

(a) An occasional carcinoma of the fundus may be overlooked. The association of fundal carcinoma and myoma is common.

(b) A pregnancy may be present but not recognized, and therapeutic irradiation is then likely to be followed by injury to the woman and the fetus. If the pregnancy goes to term, the child may be microcephalic or present other malformations.

(c) Other intrauterine lesions, such as polypi, may be present.

Irradiation by radium has the advantage that it is completed at one sitting, and does not require any longer hospitalization than does curettage alone. The X-ray, on the other hand, requires a number of

treatments continued over quite a long period of time. X-ray in combination with radium may be employed with advantage for large tumors when the more radical operation is contra-indicated. To irradiate with radium or X-ray without making certain of the condition of the endometrial cavity, or in the case of a doubtful diagnosis, is extremely hazardous and absolutely unjustifiable. The importance of these two points can hardly be overestimated and are too often overlooked, especially by X-ray specialists who are not skilled in pelvic diagnosis.

Irradiation with radium is the method of choice: (a) in small or medium-sized uncomplicated myomata with hemorrhage as chief symptom, when occurring in women approaching the menopause; (b) when surgery is contra-indicated by the presence of grave pulmonary, cardiac, or renal disease, or other conditions which would make operation unduly hazardous; (c) in some cases where it may be utilized deliberately as preliminary to the removal of the tumor.

In the John Goodrich Clark Gynecological Clinic, about 20 to 25 per cent of myomata are treated by radium irradiation. In suitable cases irradiation possesses the advantages of a lower mortality, and shorter hospitalization and convalescence, and in the event of failure does not mitigate against

the success of the subsequent removal of the tumor. The technic of radium irradiation is simple. The danger lies in its employment in unsuitable cases.

Preliminary Treatment.—This consists in the usual preparations which would be employed for a curettage and includes an examination of the heart, lungs, urine, blood, and blood-pressure, and in many cases the sedimentation test. If the hemoglobin is under 40 per cent, a blood-transfusion is indicated.

Anesthesia.—Irradiation may be given under local anesthesia, but a general anesthetic is preferable. The administration of from one-sixth to one-quarter of a grain of morphine sulphate and one one-hundredth and fiftieth grain of atropin one hour before the operation diminishes the discomforts of the anesthesia, reduces the amount of anesthetic necessary, and lessens the postoperative pain. Nitrous oxide and oxygen is the anesthetic usually employed by the author. In cases of a doubtful diagnosis, and in order to secure greater relaxation, a few inhalations of ether may be administered. A careful pelvic examination should precede the operation in all cases.

Operation.—A thorough dilatation and curettage is performed, and all the curettings saved. They are inspected for gross changes, and then immediately placed in a 4-per-cent formalin solution.

The specimen bottle is shaken to prevent clotting of the blood, and the patient's name is written on the label. The specimen is then treated by the "quick paraffin method," so that slides may be ready for examination the following morning.* Immediately upon the completion of the curettage, 50 mg. of properly screened radium enclosed in rubber tubing is inserted to the fundus, and the lower portion of the tubing stitched to the cervix so that the end protrudes into the vagina. A light vaginal pack is inserted, and the bladder emptied with a catheter. The usual postoperative technic is employed and the vaginal pack and radium removed at the end of twenty-four hours. If no complications develop, the patient is allowed out of bed on the third day, and permitted to go home on the fifth. No special postoperative precautions are necessary. A small proportion of patients complain of slight leucorrhea, which may continue for a month or two. In such cases an occasional vaginal douche is advisable. Patients who have been treated should be kept under observation for at least one year, with examinations every two or three months. The postoperative follow-up is important. Although I have never had it occur, it is nevertheless possible to mistake a sarcoma for a myoma and follow-up in

* For technic of quick paraffin method see page 94 under "Carcinoma of the Fundus."

this event would show the tumor increasing in size. Postirradiation benign degeneration of the tumor is rare but may occur, and many other conditions may develop. As long as any symptoms are present, or as long as the tumor is palpable, routine follow-up should be continued.

By radium irradiation about 90 to 95 per cent of suitable cases may be cured of all symptoms. If later a recurrence of bleeding occurs, a second treatment may be given or the tumor removed, as may seem advisable in the individual case. In our own clinic, 92 per cent of cases were cured of all subjective symptoms by a single radium irradiation. An additional 4 per cent were cured by a second application of radium, while the remaining 4 per cent required removal of the tumor. This series included a number of patients in whom, on account of age or for some other reason, only small doses of radium could be given, and it is among these that the greatest number of failures occurred.

After irradiation there may be one menstrual period, followed by amenorrhea. If the irradiation has been performed shortly *before* a period, this is likely to happen. When irradiation is given shortly *after* a period, the amenorrhea as a rule develops immediately. The production of the irradiation menopause has already been considered. Women vary markedly in their reaction to castration. The

younger patients usually suffer more, but this is not always the case. The individual temperament of the patient is a more accurate guide. The married, high-strung, and nervous types are prone to suffer the most. The severity and frequency of the menopause produced by radium are about the same as in that following bilateral oöphorectomy, and, like the surgical menopause, is prone to be more sudden in onset, of greater severity, and of shorter duration than the normal.

In our own cases [49] we found that, when a dosage of 1,200 mg.h. was employed, climacteric symptoms, including the checking of the menstrual function, occurred in varying degrees of intensity in 60 per cent of patients. In 36 per cent, these symptoms were marked, and in 5 per cent severe. As a rule they persisted for a few months to a year or more. With the smaller doses, of from 400 to 600 mg.h., recommended for young women, permanent amenorrhea was not induced. In some cases amenorrhea and nervous symptoms developed and continued for three to nine months, to be followed by return of normal menses and disappearance of the flushes and other nervous phenomena.

For the nervous symptoms associated with this condition, mental and physical hygiene and an outdoor life are of prime importance. Extract of whole ovary, combined with thyroid, seems to be helpful

in some cases, but cannot be relied upon. It is best given by hypodermic injection. In some cases the benefit is probably mental. I have never observed a recurrence of bleeding or growth of the tumors, even after large doses of ovarin extracts.

The majority of women requiring radium irradiation have passed the child-bearing period, and conception and subsequent normal pregnancy have, furthermore, been rendered impossible by the distortion of the uterus incident to the myoma. Among 527 previously reported cases [49] which were treated by irradiation, most of whom were older women, 5 (less than 1 per cent) subsequently became pregnant. All of the pregnancies occurred in younger women who had been treated with small doses of irradiation. There is no evidence to show that preconception irradiation is deleterious to the infant. Murphy has shown—by animal experimentation and by a study of clinical material—that fetuses conceived after irradiation are usually normal.

Surgical Treatment.—In suitable cases irradiation is to be preferred to surgical measures because of its efficiency, and lack of mortality and morbidity. Many cases are, however, not suited for irradiation, and these should be treated by surgical intervention. If removal of the tumor is indicated, myomectomy is the operation of choice. This conserves fertility as well as menstrual function, and is espe-

cially suitable for young patients. In some cases it carries a lower mortality than does hysteromyomectomy, especially when single pedunculated tumors are present. The chief disadvantage of myomectomy is that small intramural tumors may be overlooked which may subsequently develop and require a second operation. Even with the most careful examination this risk cannot be completely excluded. As a matter of fact, the number of recurrences in skilled hands is small and should average considerably under 5 per cent.

The situation, size, number of tumors, condition of the adnexa, age of the patient, and her wishes regarding subsequent fertility, should all be taken into consideration when deciding between myomectomy and hysteromyomectomy. The patient's consent to the removal of the uterus should always be secured before the anesthetic is administered, as after the abdomen has been opened conditions may be found which preclude myomectomy.

Patients upon whom myomectomy has been performed, and who subsequently become pregnant, must be individualized. The danger of rupture of the uterine scar during labor should here be taken into consideration. All such cases should be delivered in a well-equipped maternity hospital where immediate abdominal section can be performed in case of necessity. In cases in which only small

uterine wounds have been necessary, and in which convalescence has been afebrile and every indication of a strong scar is present, the chance of rupture is small if the infant is of normal size and in normal position.

When the reverse has been present, Cesarean section before the onset of labor may be the safest procedure. Vaginal myomectomy is rarely, if ever, an indication for subsequent section.

Vaginal Myomectomy.—Pedunculated submucous tumors, when accessible from below and not associated with other varieties, are best removed by vaginal myomectomy. Necrotic submucous pedunculated tumors should be removed from below, even if other myomata are present. Abdominal removal is hazardous on account of the infection which is generally present. The remaining myomata may be removed subsequently or treated by irradiation. In order to secure a sterile field, the interval between the vaginal and abdominal operation should be of considerable duration. A preliminary vaginal myomectomy is not a contra-indication to subsequent irradiation, provided the case is otherwise suitable for this form of treatment.

Vaginal myomectomy is indicated in certain cervical myomata. Avulsion is a satisfactory method in some cases, while excision or ligation of the pedicle is the operation of choice in other instances.

Cauterization of the stump is advisable if necrosis or other evidence of infection is present. The uterine cavity should not be packed.

Abdominal Myomectomy.—This is the operation of choice when the tumors are subperitoneal, and especially if they are pedunculated. Intramural tumors may also be removed by this operation. When the tumors are few in number, small, can be removed without opening the endometrial cavity, and are of such a character that a moderately normal uterus can be conserved, abdominal myomectomy is a very satisfactory operation. It is, however, rarely advisable in cases where ovarian disease makes a bilateral oöphorectomy necessary. The uterus without the ovaries is a useless organ and may cause subsequent trouble, and therefore, if the ovaries cannot be conserved, a supravaginal hysteromyomectomy is generally preferable. The mortality in properly selected cases is about the same with abdominal myomectomy as with supravaginal hysteromyomectomy. In single pedunculated tumors the mortality is lowered, while opening the endometrial cavity increases it. Asepsis and hemostasis are essential for the success of myomectomy.

Myomectomy is contra-indicated if there is any doubt as to the benign character of the tumor. The uterus and ovaries should be left in good position,

and careful peritonealization is essential for the subsequent comfort of the patient. As in all gynecological operations in which pelvic infection is not present, a thorough examination of the upper abdomen should be a part of the routine and should include the gall bladder, stomach, and palpation of the kidneys and ureters. The appendix should be inspected. Provided the patient's condition permits it, all intraperitoneal lesions should be appropriately dealt with. In our own clinic the appendix is usually removed as a part of the routine in all intraperitoneal operations, unless this performance is contra-indicated. Myomectomy should be immediately preceded by curettage, and the endometrium submitted for histologic examination.

Supravaginal Hysteromyomectomy.—This is the operation of choice for the majority of cases in which symptoms are being produced by the tumor. The mortality rate is somewhat under 2 per cent, and the morbidity rate low. It is an extremely satisfactory form of treatment, and the end-results are excellent.

Panhysteromyomectomy is the operation of choice in those cases in which there is disease of the cervix, or in which cervical myomata are associated with the fundal tumors. It is also indicated when there is any doubt as to the benign character of the uterine tumors, as in the case of a myoma

suspected of sarcomatous change, or when myomata are associated with carcinoma.

The advantages of supravaginal *vs.* panhysteromyomectomy has been the subject of much discussion. The occasional subsequent development of carcinoma in the cervical stump left after the supravaginal operation has been used as an argument for the routine employment of the more radical procedure. In previous pages it has been shown that carcinoma rarely develops in the normal cervix, and that sarcomatous change in myomata is an event of even more rare occurrence. By removing the cervix in all cases in which it presents evidence of disease or in which the myomata are under suspicion of undergoing sarcomatous change, the risks of the subsequent development of either carcinoma or sarcoma in the cervical stump are largely eliminated. Even if supravaginal hysteromyomectomy is performed routinely, the danger of the later development of carcinoma or sarcoma in the stump is not great. Cauterization of the cervical canal from above not only tends to prevent postoperative inflammatory complications, but also further minimizes the danger of the later development in the stump of either form of malignancy.

The incidence of carcinoma is about the same in the cervical stump as in the cervix from which the fundus has not been removed. Apart from the ques-

tion of the subsequent development of either carcinoma or sarcoma, panhysterectomy is indicated in those cases in which cervicitis is present because, if the cervix is conserved, the leucorrhea incident to the cervicitis will continue and be a cause of discomfort. The disadvantages of panhysterectomy are that the vagina is necessarily somewhat shortened, the uterosacral and uterovesical ligaments are cut, and there is greater likelihood of prolapsus of the upper vagina. The operation is longer and more difficult, and the danger of injury to the ureters and bladder are greater. Although by no means a difficult operation for the experienced pelvic surgeon, panhysterectomy gives a somewhat higher mortality. In a certain proportion of myoma cases it is of distinct advantage to deliberately perform the amputation at a higher level in order to preserve functioning endometrium. By this operation menstruation may be preserved, provided conservation of an ovary is possible. The ovaries undoubtedly function better if a certain amount of endometrium can be conserved.

Treatment of the Adnexa.—In women at or past the menopausal age it is preferable to remove the adnexa if a hysterectomy is performed, while in young women the conservation of normal ovaries should be practiced. Conserved ovaries occasionally undergo cystic degeneration, but this is infrequent if

their blood-supply is unimpaired and they are left in normal position. Adequate blood-supply to an ovary is more easily secured if the tube is left intact. The conserved ovaries function better if the amputation of the uterus can be performed at such a level as to leave behind some endometrium. However, even if this is inexpedient and the menstrual function is destroyed, the presence of ovaries prevents development of the nervous symptoms which are such an uncomfortable feature of the surgical menopause in the majority of cases. Patients on whom ovarian conservation has been practiced are generally more comfortable than those on whom a complete operation has been necessary.

If the ovaries are seriously diseased their removal is indicated, as a painful ovary usually is worse than the artificial menopause. If both ovaries are in good condition they should both be spared, but one is far better than none. When the ovaries have been conserved in a hysterectomy, their active life is probably somewhat shortened. But if they only function for a year or two, the menopause is more gradual and analogous to the normal than if a bilateral oöphorectomy had been performed. Occasionally an unavoidable injury to the blood-supply, or some other condition, renders it inadvisable to conserve even one ovary. In these cases ovarian grafts may sometimes be of value. Im-

mediately upon removal a thread is attached to the ovary, which is then placed in the cul-de-sac or among the coils of intestine, where it may be kept warm and moist until the operation is completed. The operation is performed in the usual manner, and the peritoneum closed except for a small opening at one end of the incision through which the ovary is withdrawn by means of the attached suture. The ovary is decapsulated and divided into small pieces, not larger than 8 x 4 x 4 m.m. These are now grafted into the rectus muscle, a separate pocket being made for each. Hemostasis is essential. Practically all such grafts "take." Their life probably does not last more than two to three years, but the menopause is rendered more gradual and less severe. It requires from two to seven months for the grafts to become vascularized and begin to function. After that time it is not uncommon for the graft to become slightly tender for a day or two each month, this tenderness probably corresponding to the period during which a follicle is matured. In thirty-one cases in which grafts were employed by the author, and which were studied for periods varying from six months to three and a half years, none required removal and the results were generally satisfactory.[50] Grafting in the rectus has the advantage that, if the transplant gives sub-

sequent trouble, its removal is a minor procedure and does not involve opening the peritoneal cavity.

As has been previously stated, women react variably to the removal of the ovaries. Some do not suffer at all; in others the discomfort is moderate; and in a small but definite proportion the reaction is extremely severe. Everything else being equal, young women suffer most. The temperament of the patient is, however, an even better guide. The highly strung, nervous, and idle woman is likely to suffer most. In negroes the surgical menopause is generally mild or absent, but this is not always the case.

Treatment of Patients Suffering from Marked Anemia.—Occasionally patients suffering from myomata are encountered, in which the anemia is so severe as to make operation or even curettage and radium irradiation hazardous. The preliminary treatment is here very important. All such patients should be immediately hospitalized. They may be divided into three groups: (a) those which are suitable for radium irradiations; (b) those requiring vaginal myomectomy; and (c) those which will ultimately need an abdominal operation. In any event, it is advantageous to have the patient in the best possible condition for whatever operation is required, although the risks of performing an abdominal operation in the face of marked anemia

are obviously much greater than when the less radical procedure only is necessary.

In some cases there is a history of fairly regular periodicity of the hemorrhages. Under such circumstances operation should be performed just before the hemorrhage is expected. Rest in bed, an ice-bag to the lower abdomen, and the administration of ergot are adjuncts to the treatment. Blood transfusion is perhaps the most valuable single measure, and may be repeated at frequent intervals.

X-ray irradiation as a preliminary to either operation or radium irradiation is extremely valuable. Like radium irradiation, X-ray treatment may require some weeks to permanently check hemorrhage due to ovarian action. It would seem, however, that X-ray irradiation often temporarily checks hemorrhage immediately by what H. K. Pancoast and E. P. Pendergrass [51] term a "primary reaction." The first result of irradiation by either X-ray or radium is an aseptic inflammatory reaction, as instanced by edema and infiltration of the exposed area with inflammatory products. In all events, it is a clinical fact that X-ray irradiation over the tumor in some cases checks the hemorrhage within a few hours, and for this reason it should be given routinely and without delay to all patients suffering from grave anemia. In cases of severe anemia a number of weeks may well be employed in im-

proving the patient's general condition, provided further hemorrhage can be prevented during this time.

Patients with inflammatory lesions of the adnexa, or in whom degeneration of the tumor has occurred, should not, as a rule, be subjected to Roentgen therapy. X-ray treatments may be given to bed patients, and is especially valuable in those cases in which operation is likely to be delayed for some weeks. Even if the X-ray has been employed and it is later decided to operate earlier than was at first proposed, no harm has been done.

The author has seen hemorrhage checked in a few hours following one treatment with the X-rays in a case desperately ill, and anemic, in which the hemorrhage had been present for over a year and the bleeding constant for two months, and in which all other attempts at checking the bleeding had failed. This primary action is, however, uncertain.

Diet is one of the most important means of combating anemia. It should be abundant, and pushed to the capacity of the patient. The food should be nourishing and easily digestible. The value of liver has been amply proven. Murphy and Powers [52] have shown that liver stimulates the formation of hemoglobin and red blood corpuscles. Furthermore, liver is apparently easily digested,

and well borne by the average patient. Iron, preferably by hypodermic injections, should also be administered. The patients should be wheeled out-of-doors and kept in the open air as much as possible. If the weather is cold a well-warmed sun parlor may be utilized, but there is no substitute for sunlight.

Considerable surgical judgment is necessary to determine the most favorable time to operate. In general it is best to delay operation as long as the patient's general condition is improving. The danger in delay is that another hemorrhage may occur, and as a result the patient loses all that she has gained. This risk can be largely eliminated by the preliminary X-ray irradiation, the castrating effects of which may develop before the onset of the next hemorrhage. In some instances the patient may be carried along until the approach of a hemorrhage, a curettage and radium then employed, and the removal of the tumor delayed until further improvement has occurred. Packing of the vagina or uterus is of questionable value, and certainly should be reserved for desperate cases.

Anemic patients are poor surgical risks, are more prone to develop complications, and are especially susceptible to infection. As a matter of fact, women bear hemorrhage better than men and generally

respond well to treatment. This does, however, not mean that every effort should not be made to get the patient in the best possible condition before operation. At operation, properly administered anesthesia is particularly important, the operation should be performed as expeditiously as is compatible with good work, and unnecessary loss of blood should be especially guarded against. In certain cases auto-transfusion is valuable. The blood lost during operation should be siphoned out of the pelvis, then filtered, citrated, warmed, and immediately introduced into a vein. Postoperative transfusions are also of value.

Pregnancy and Myoma.—The size and position of the tumors sometimes makes it obvious, even during the early months of pregnancy, that the birth of a living child is a physical impossibility. Under these circumstances the pregnancy should be disregarded, and treatment directed toward eradication of the tumor, generally by abdominal section. In other cases an abdominal Cesarean section shortly before term, combined with either a myomectomy or a hysteromyomectomy, is the most satisfactory procedure.

Myomectomy during pregnancy is rarely indicated. During the early months of pregnancy it may be followed by abortion, and in the type of case

which is suitable for myomectomy the tumors will rarely interfere with pregnancy and labor. In the later months, myomectomy is likely to be followed by premature labor, which, occurring shortly after an abdominal section, is likely to tear out the stitches in the uterine or abdominal wound or result in other complications. In general, if an abdominal operation is required in the last few months of pregnancy, it should be combined with a Cesarean section. In the majority of cases watchful waiting is the principle to be adopted. In the early months abortion may result, and in this event treatment of the myoma should be delayed until complete convalescence has taken place. In the later months premature labor may occur, but, even if the pregnancy goes to term, a surprisingly large number of cases may be successfully delivered through the normal channel. During labor the myomata tend to become softened and are often drawn upward or pushed to one side, permitting the passage of the child in cases in which grave dystocia appeared almost certain prior to the onset of labor. Degeneration of the tumor, and especially necrosis, should be watched for during pregnancy and the puerperium, and frequent blood-counts and other safeguards inaugurated. When the tumor blocks the birth canal, abdominal delivery is necessary.

ADENOMYOMA OF THE UTERUS

Adenomyomata are of two varieties—circumscribed and diffuse. Glandular structures are present in about 5 to 8 per cent of all myomata.

Etiology.—Many theories have been advanced to explain the presence of glandular tissue in these tumors. According to Graves,[10] von Rokitansky [52] deserves priority in that, in 1860, he described adenomyoma as a pathologic entity. Later von Recklinghausen [53] studied these tumors, and came to the conclusion that they developed from remnants (rests) of the Wolffian ducts. In 1896 Cullen [54] advanced the view that the adenomatous condition was the result of an ingrowth of endometrium into the tumor. Russell,[55] Pick,[56] Koch, Casler,[57] Schwarz,[58] Cullen,[63, 64] Bell,[59] Shaw,[60] Donald,[61] Norris,[62] and others reported the presence of endometrium-like tissue in the ovary and in other localities outside of the uterus.

Endometrium-like tissue has been found in the rectovaginal septum: (Curtis,[65] Cullen,[66]) at the tubal angle (Von Franque [67]) in the round ligament, (Cullen,[63] Sitzenfrey [69]) utero-ovarian ligament, (Cullen, Frankl [70]) umbilicus, (Cullen,[68] Mahbe, and MacCarthy [71]) peritoneum, mesentery, and laparotomy cicatrices. Meyer [72] believes these lesions to be the result of a metaplasia of the serosa,

an opinion which is shared by Novak.[73] Halton considers heterotopic endometriomata as metastatic in origin, the endometrial elements reaching their new location through the lymphatics.

In 1921 Sampson [34] advanced the theory that the endometrium-like tissue found in the ovary was the result of transtubal dissemination of portions of endometrium desquamated at menstruation, which had seeded and developed upon this and adjacent areas. The chief arguments for this theory are: (a) it is known that more or less desquamation of the superficial endometrium occurs at menstruation. (b) The implants are of frequent occurrence. Sampson found these growths in 43 per cent of women between the ages of thirty and fifty years, who had been operated upon for intraperitoneal pelvic lesions. (c) Embryonal rests are infrequent. (d) The implants morphologically resemble endometrium. (e) Menstrual blood containing shreds of endometrium has been frequently observed in the tubes at operations performed during the menstrual period. (f) The implants undergo the same cycle of changes as does the endometrium of the body of the uterus, and at the same time. Thus, premenstrual, menstrual, postmenstrual, and interval changes occur in the implants synchronously with similar changes in the corporeal endometrium, and in the event of pregnancy changes like those in

the decidua are also observed in the implants. (g) Implants are most common in areas adjacent to the distal end of the tubes. (h) Implants are infrequent except in association with patent tubes, and the few instances in which the tubes are occluded may be accounted for by closure of the tubes after the passage of the endometrium. (i) In the majority of cases implants are found in association with some lesion which tends to retard the escape of the menstrual blood, such as obstructing myomata or retroflexion. (k) Implants have been produced experimentally. Fresh curettings introduced into the peritoneal cavity result in lesions identical with endometriomata (Jacobson,[74] Michon [75]). (l) Desquamated endometrium may be viable as demonstrated by Cron [76] who grew such tissue in vitro, and maintained its activity for one month.

Thus, three principal theories have been advanced to explain the presence of endometrium-like tissue outside of the uterus: (1) that this tissue is derived from embryonal rests; (2) that it is the result of a transition of the serosa; and (3) the implantation theory of Sampson.

Adenomyoma of the uterus probably occurs in two ways: (a) by a direct outward growth of the normally situated endometrium (into the myometrium or into a myoma as the case may be) as described by Cullen; or (b) by an ingrowth into

the uterine wall from the outside of extra-uterinely situated endometrial-like tissue.

The stimulus starting this activity of the glandular tissue is unknown.

Circumscribed Adenomyoma.—Clinically and pathologically these are merely fibromyomata which contain endometrial-like structures. The glands are similar to those of the endometrium but may be altered as a result of pressure and growth of the tumor. The glands are usually relatively few in number.

These tumors are commonly found in association with myomata. Macroscopically the tumors resemble ordinary fibromyomata except that, on section, small blood-containing cystic spaces are seen. These commonly vary from a few mm. to 1 c.m. or more in diameter, although large cystic spaces have been observed. The contents may be thin bright blood, clot, chocolate-like or tarry material.

Histologic examination presents the usual appearance of a myoma, with islands of endometrium sparsely scattered throughout the tumor. These may consist of glandular tissue, stroma or glands and stroma. As the tumor develops, the intraneoplastic endometrium tends to become separated from its source. Pressure or occlusion of the glands occurs. At each menstrual period blood is discharged into the gland lumina. These gradually become dis-

tended, and finally result in the small blood-containing cysts previously referred to. As a result of pressure, alteration in both glands and stroma takes place, which is especially noticeable in the glands and glandular epithelium. The endometrium within the tumor is subjected to the same stimulus as that within the uterus, and undergoes the same cycle of changes. Because of the pressure and confined space, these changes are often less typical in the tumor than in the normally situated endometrium.

The tumors are subject to the same degenerative changes as occur in the glandless myomata. A rare complication is the development of an adenocarcinoma in the substance of the tumor.

Circumscribed adenomyoma may be suspected when on section, a small blood-containing cyst is observed, but the positive diagnosis can be made with the microscope only.

The symptoms, prognosis, and treatment of circumscribed adenomyoma of the uterus are the same as those of fibromyoma.

Diffuse Adenomyoma.—Both this and the foregoing tumor are regarded by some authorities as forms of endometriosis, and with more reason in the case of the diffuse variety. The circumscribed tumor is generally found in association with endometrium-free fibromyomata and, therefore, it seems probable

that the fibromyoma is the primary condition and that for some reason this is invaded by endometrium, probably early in the tumor's existence. There are many reasons from the belief that the first step in the development of the diffuse variety is an invasion of the myometrium by the endometrium either from within or from without, and that the myomatous development is secondary and of the character of a reaction against a foreign body.

Diffuse adenomyomata are rarely larger than a three and a half months pregnancy. The normal shape of the uterus is more or less preserved, while there is a diffuse thickening of the myometrium, especially in the anterior and posterior walls. In most cases the lateral uterine walls are also thickened. The myomatous tissue is firm, coarsely striated, and rather loosely arranged, and tissue morphologically identical with the endometrium is found in the interstices. The endometrium itself may be altered as a result of pressure.

The tumor generally consists of both glands and stroma, but Cullen [54] has described a specimen in which only stroma was present. The amount of endometrium is relatively greater in this variety than in the circumscribed. Endometrial cysts containing blood are often present.

The tubes are generally patent, the seat of adhesions, and more or less tortuous. The ovaries

FIG. 13.—*Diffuse Adenomyoma* of the uterus. The myomatous thickening is chiefly in the inner and middle muscular layers of the uterus. The myomatous tissue is infiltrated by edometrial-like tissue. Some of the glands have become cystic and are filled with dark chocolate-like blood. The condition is often associated with Sampson's cysts of the ovaries and is perhaps a form of endometriosis.

frequently contain Sampson's cysts, and endometriomata are often present in adjacent areas.

Diffuse adenomyomata may occur any time between puberty and menopause, but are most common in women thirty-five to forty-five years of age. Menorrhagia, dysmenorrhea, and tenderness are the chief symptoms. The evolution of the symptoms is slow. The menorrhagia is progressive, but may have been present for three or four years. The dysmenorrhea develops shortly before the onset of the flow, centers over the uterine region and usually becomes less marked after the second or third day of bleeding. Uterine tenderness often precedes the flow by some days, and continues until the hemorrhage ceases. The tenderness is often sufficiently marked to prevent the wearing of a waistband, and be complained of even on slight pressure.

Anemia with its accompanying manifestations may result from the loss of blood. If a diagnostic curettage is performed, the endometrium may be found normal, thickened, or hyperplastic.

The menorrhagia, dysmenorrhea, and tenderness associated with the enlarged but more or less symmetrical uterus, should make the diagnosis possible in the majority of cases. Another feature of diagnostic value is that the uterus becomes slightly larger and more tense at and just before the onset of bleeding.

The most satisfactory treatment is supravaginal hysterectomy, with, if conditions warrant it, the conservation of tubes and ovaries. It should be remembered that a diffuse adenomyoma of the uterus is often only a part of an endometriosis. Irradiation—employed as in the treatment of fibromyomata—checks the progress of the disease, and usually produces a shrinkage of the uterine growth as well as other lesions. The reduction in the size of the tumor is frequently not appreciable for months and, as many patients suffer from adhesions and in addition often are relatively young, removal of the uterus is usually the more satisfactory treatment.

Radium irradiation is the method of choice in patients who are close to the menopausal age, or who are markedly anemic or present some grave contra-indication to the more radical operation. X-ray therapy may be substituted for radium irradiation, but in this case a preliminary diagnostic curettage should be performed. The prognosis is good.

Cullen [54] has observed an adenocarcinoma developing upon an adenomyoma, and also cases of cervical and fundal carcinoma in association with these tumors. Carcinomata arising from adenomyomata have also been described by Meyer,[77] Dillman,[78] and Sitzenfrey,[79] and a sarcomatous adenomyoma

has been reported by Bauereisen.[80] Malignant change is, however quite rare.

ENDOMETRIAL POLYPS

Endometrial polyps are localized hypertrophies of the corporeal mucosa. The cause of these little tumors is unknown. They were formerly thought to be inflammatory in origin, but this has been disproved, and evidence of inflammation is rarely present. An endocrinial origin is more probable, and this theory is supported by the fact that these tumors often show hyperplasia, or are associated with this condition. Hyperplasia is generally believed to have an ovarian origin.

Endometrial polyps are small neoplasms rarely more than a few centimeters in their greatest length. They are commonly oval, triangular, or tongue shaped, and usually correspond, more or less, to the outline of the endometrial cavity. They are flattened in their anteroposterior diameters and correspond in color to the endometrium. As a result of infection or vascular change, they may be bright red. This is especially likely when the new growth is pedunculated and the tip presents low in the endometrial cavity. Polyps may be sessile but are more often pedunculated. The pedicle may be long, gracile, and as a result, the tumor cervical or even vaginal in situation. They are soft, rather friable,

and of a consistency similar to that of the endometrium. The surface is smooth, glistening, and resembles that of the normal endometrium. Frequently small cystic glands are detectable with the naked eye, and sometimes, especially the larger tumors, present almost a honeycomb-like appearance. Areas of degeneration appear yellow, brown, black or vivid red.

Endometrial polyps may undergo carcinomatous change either from extension via the lymphatics in the pedicle, from contact growth, or the cancer may be primary in the lesion. Sarcomatous change is of rare occurrence. Malignant changes in these tumors occur in something less than 1 per cent of the cases, and are most common in patients of over 40 years of age. Endometrial polyps are more commonly single than are similar tumors of cervical origin. In some specimens the entire corporeal endometrium undergoes a polypoid change—the so-called diffuse polyposis, and formerly designated polypoid endometritis—although no true inflammatory change was present.

Histologically endometrial polyps are composed of endometrium. This usually resembles the normal mucosa and is subject to the same changes. As a result of vascular disturbances and pressure, alterations are common. Hyperplasia is frequent and may be marked in the tumor associated with a normal

endometrium, or the latter may also be hyperplastic. If hyperplasia is present, the "Swiss-cheese" pattern and the fact that the tissue comprising the tumor does not present the changes resulting from the menstrual cycle, are distinguishing features. Oedema, thrombosis of the blood vessels or actual rupture of the latter are of common occurrence. Areas of erosion, desquamation or flattening of the surface epithelium are frequently present, especially toward the tip of the tumor.

Symptoms.—Endometrial polyps are of frequent occurrence and are most common between 35 and 55 years of age. They are especially frequent in myomatous uteri. The majority of polyps are symptomless. They may cause atypical bleeding, usually of the menorrhagic type, but when undergoing degeneration or vascular changes may result in metrorrhagic hemorrhage. Profuse bleeding may occur, but is unusual. It often follows trauma in those cases in which the tumor presents at the cervix. A slight, thin, watery discharge is often present which may be irritating and malodorous as a result of degeneration or infection. Polyps are of slow growth and symptoms may have been present over a prolonged period.

The *diagnosis* is usually impossible prior to dilatation of the cervix, however, polyps which possess long pedicles may be palpable or demonstrable

through a speculum at the external os. Under the latter circumstance, the polyp may be felt as a small, soft, smooth, movable tumor at the cervical opening, or even in the vagina. Endometrial polyps are softer than those originating in the cervix. The presenting part is often bright red, but may be darker as a result of necrosis. Curettage may break up the polyp so that it is unrecognizable except with the microscope.

Treatment.—Pedunculated polyps may be twisted off with a hemostat, and when possible the base of the pedicle touched with the cautery. Avulsion rarely results in bleeding, and packing or ligation to prevent hemorrhage is not often necessary. As, however, multiple tumors may be present, or the bleeding result from some other intrauterine lesion, a diagnostic curettage should follow polypectomy. Otherwise, to a symptomless polyp may be attributed an atypical bleeding which is really due to a fundal carcinoma. The polyp and curettings should be examined histologically. If a carcinoma is present, even if it appears confined to the polyp and the pedicle appears normal, a pan hysterectomy is the safest treatment. Care should be exercised not to attribute new gland formation, benign degeneration, and alterations due to pressure, infection, or vascular change to malignancy. These are of

common occurrence, but can readily be distinguished by the competent gynecological pathologist.

REFERENCES

[1] Kelly and Cullen, *Myomata of the Uterus*, Philadelphia and London, 1909.

[2] Mallory, *Jour. of Exper. Med.*, 1908, vol. x, no. 5.

[3] Frank, R. T., *Gynecological and Obstetrical Pathology*, New York and London, 1922.

[4] Moller, E., "Klin. u. Path. Stud. z. Aetiol. d. Uterusymome," *Mit. a.D. Klin. Engström zu Helsingfors*, vol. iii, no. 1.

[5] Young, E. B., and Williams, T. J., *Boston Med. and Surg. Jour.*, 1911, no. 165. p. 836.

[6] Phillips, T. B., *Nederl. tijdschr. v. geneesk.*, Amsterdam, 1914, p. 631.

[7] Olshausen, *Veit's Handbuch d. Gynäk.*, 1897, vol. ii.

[8] Lynch, F. W., and Maxwell, A. F., *Pelvic Neoplasms*, New York and London, 1922, p. 106 (appendix).

[9] Uchigaki, *Jap. Jour. Obst. & Gyn.*, 1928, vol. ii, p. 61.

[10] Graves, W. P., *Gynecology*, Philadelphia and London, 1928, p. 343.

[11] Ulesko-Stroganowa, K., *Arch. f. Gynäk.*, 136, 1929.

[12] McDonald, E., *Jour. Am. Med. Assn.*, 1909, vol. xciii.

[13] Quoted in Ewing, *Neoplastic Diseases*, Philadelphia, 1919, p. 201.

[14] Müller, *Verhand. d. Deut. Ges. f. Gynäk.*, 1891, 283.

[15] Hofmeri, *Ztschr. f. Geb. u. Gyn.*, vol. v, p. 96.

[16] Leo, *Cent. f. Gyn.*, 1913, vol. xxxvii, p. 467.

[17] Doler, *Soc. d'Obst. et de Gynéc. et de Péd. de Paris*, 1901.

[18] Küstner, *Cent. f. Gyn.*, 1904, vol. xxviii, p. 1519.

[19] Lockyer, C., *Practice of Surgery*, Hagerstown, Maryland, 1928, vol. xi.

[20] Clark, J. G., *Johns Hopkins Hospital Bulletin*, 1899, vol. x, No. 2.

[21] Sampson, J. A., *Surg., Gyn., & Obst.*, 1913, vol. xvi, p. 144.

[22] Virchow, *Die Krankhaften Geschwülste*, Bd. iii, p. 201.

[23] Chrobak, *Arch. f. Gyn.*, 1872, Bd. iv, p. 549.

[24] Ritter, *Ueber d. Myosarkom. des Uterus* (*Dissert. Inaug.*), Berlin, 1887.

[25] Williams, J. W., *Am. Jour. of Obst.*, 1894, vol. xxix, no. 6.

[26] Schreher, *Dissert. Inaug.*, Jena (Strassburg), 1894.

[27] Pick, L., *Arch. f. Gynäk*, 1895, p. 33, and *Arch f. Gynäk.*, 1895, vol. xlix, p. 1.

[28] Gessner, *Veit's Handbuch der Gynäk.*, 1899, vol. iii.

[29] Hunter, *Am. Jour. Obst.*, 1888, vol. xxi, p. 62.

[30] McDonald, E., *Brit. Emp., Jour. Obst. and Gyn.*, 1909, vol. xvi, p. 84.

[31] Meyer, R., *Arch. f. Gynäk.*, 1920, vol. cxiii, p. 250.

[32] Schröder, R., *Arch. f. Gynäk.*, 1915, vol. xxvii, p. 102.

[33] Novak, E., and Martzloff, K. H., *Am. Jour. Obst. and Gyn.*, 1924, vol. viii, p. 385.

[34] Sampson, J. A., *Trans. Am. Gyn. Soc.*, 1921, p. 162.

[35] Ransohoff and Dreyfoss, *Surg., Gyn., & Obst.*, 1921.

[36] Peightal, T. C., *Am. Jour. Obst. & Gyn.*, 1929, vol. xvii, No. 3, 363.

[37] Piquand and Limeland, *Rev. de Gynéc. et de Chir. Abdom.*, 1908, vol. iii, p. 377.

[38] Hitzanides, *Gynéc. et Obst.*, 1926, vol. xiii, p. 103.

[39] Hofmeier, quoted by Lynch, *Am. Jour. Obst.*, 1913, vol. lxviii, p. 427.

[40] Scipiades, "Myom und Schwangerschaft. II. Komplikation des myoms mit Gravidität," *Abhand. a.d. Geb. d. Geburt. u. Gynäk.*, Berlin, 1913, vol. ii, p. 201.

[41] Peham, quoted by Lockyer, C., *Practice of Surgery*, Hagerstown, Md., 1928, vol. xl, p. 33.

[42] Goetze, *Ztschr. f. Geburtsh. u. Gynäk.*, Stuttgart, 1910, vol. lxvi, p. 340.

[43] Lockyer, C., *Brit. Med. Jour.*, 1924, vol. i, p. 1037.

[44] Polak, J. O., *Surg., Gyn., & Obst.*, 1928, vol. xlvi, p. 21.

[45] Murphy, D. P., *Surg., Gyn., & Obst.*, June, 1929.

[46] Quoted by G. Gellhorn, *Jour. Am. Med. Assn.*, January 28, 1922.

[47] Polak, J. O., *Med. Record*, March 25, 1922.

[48] Burnam, C. F., *Am. Jour. Obst.*, October, 1924.

[49] Clark, J. G., and Norris, C. C., *Radium in Gynecology*, Philadelphia and London, 1927.

[50] Norris, C. C., and Behney, C., *Surg., Gyn., & Obst.*, 1929, vol. xlix, No. 5, p. 642.

[51] Pancoast, H. K., and Pendergrass, E. P., Personal Communication.

[52] Murphy, W. P., and Powers, J. H., *Surg., Gyn., & Obst.*, 1929, vol. xlviii, No. 4, p. 480.

[52] Rokitansky, C. von, *Ztschr. d. k.u.k. Gesell. d. Aerzte zu Wien*, 1860.

[53] Recklinghausen, E. von, *Wien. Klin. Woch.*, 1895, vol. viii, p. 530.
[54] Cullen, T. S., *Adenomyoma of the Uterus*, Philadelphia and London, 1908.
[55] Russell, W. W., *Johns Hopkins Hospital Bull.*, 1898, vol. x, p. 8.
[56] Pick, L., *Arch. f. Gyn.*, 1905, vol. lxxvi, p. 191.
[57] Casler, D. C., *Jour. Am. Med. Assn.*, 73, July, 12, 1919.
[58] Schwarz, O. H., *Jour. Obst. & Gyn.*, 1927, vol. xiii, p. 331.
[59] Bell, W. B., *Jour. Obst. & Gyn., Brit. Emp.*, 1922, vol. xxiv, p. 443.
[60] Shaw, W. F., *Jour. Obst. & Gyn., Brit. Emp.*, 1922, vol. xxix, p. 452.
[61] Donald, A., *Jour. Obst. & Gyn., Brit. Emp.*, 1922, vol. xxix, p. 477.
[62] Norris, C. C., *Am. Jour. Obst. & Gyn.*, May, 1921.
[63] Cullen, T. S., *The Umbilicus and Its Diseases*, Philadelphia and London, 1916.
[64] Cullen, T. S., *New York State Jour. Med.*, 1919, vol. xix, 295.
[65] Curtis, A. H., *Surg., Gyn., and Obst.* 1918, vol. xxvi, p. 551.
[66] Cullen, T. S., *Johns Hopkins Hospital Bull.*, November, 1917.
[67] Von Franque, *Ztschr. f. Geburtsh. u. Gyn.*, 1896, vol. xlii, p. 41.
[68] Cullen, T. S., *Johns Hopkins Bull.*, 1898, 87.
[69] Sitzenfrey, *Ztschr. f. Geburtsh. u. Gyn.*, 1910, vol. lxvii, p. 32.
[70] Frankl, *Arch. f. Gyn.*, 1911, vol. xciii, p. 659.
[71] Mahbe and MacCarthy, *Jour. of Lab. and Clin. Med.*, 1920, vol. v, p. 4.
[72] Meyer, R., *Arch. f. Path. Anat.*, 1924, vol. xxi, p. 12.
[73] Novak, *Trans. Am. Gyn. Soc.*, 1928.
[74] Jacobson, V. C., *Arch. Surg.*, 1922, vol. v, p. 281.
[75] Michon, quoted by Graves, *Gynecology*, Philadelphia, 1928, p. 447.
[76] Cron, R. S., *Am. Jour. Obst. & Gyn.*, 1927, vol. xiii, No. 5, p. 645.
[77] Meyer, R., *Veit's Handbuch der Gynäk*, i.c., 2nd ed., 1, p. 474.
[78] Dillman, *Ztschr. f. Krebsforschung*, 1904, vol. ii, 33.
[79] Sitzenfrey, *Ztschr. f. Geburtsh. u. Gynäk.*, 1910, vol. lxvii, p. 413.
[80] Bauereisen, *Betrage z. Geburtsh. u. Gynäk.*, 1904, vol. ix, p. 313.

CHAPTER V

SARCOMA AND ALLIED TUMORS OF THE BODY OF THE UTERUS

PREVIOUSLY to the year 1843 the term "sarcoma" was loosely applied to many malignant or eroding uterine neoplasms. During that year Lebert [1] called attention to the histologic characteristics of the spindle-celled sarcoma of the uterus. Subsequent to this the literature contains many references to "recurrent fibroids," "recurrent myomata," "malignant fibroids," etc., and indeed these terms are still employed by some eminent writers. Mayer [2] in 1860, Paget [3] in 1863, Virchow [4] in 1865, Veit [5] in 1867, Gusserow [6] and Hegar [7] in 1871, have all contributed to the early knowledge of these tumors.

For historic literature, see Lockyer,[8] Pfannenstiel,[9] von Kalden,[10] Williams[11] and Meyer,[12] the last-mentioned work contains a valuable bibliography. Gessner [13] has also made important contributions to this subject.

Frequency.—Sarcoma of the uterus is a rather rare tumor. Opinions formerly varied quite markedly on this point, and some clinics claimed that

sarcomatous change had occurred in as much as 10 per cent of myomata. Among the most competent pathologists and clinicians, however, the infrequency of the tumor early became recognized. Thus, the careful survey of the literature, performed by Williams[11] in 1894, revealed only 144 authentic cases; and, in 1923, Vogt[14] stated that about 500 additional cases had been recorded. Carcinoma is thirty to fifty times as frequent as sarcoma in the uterus.

The following table shows the relative frequency with which these two tumors have been observed by seven investigators:

Frank	1 sarcoma	to	30–40	carcinomata
Evans	1 "	"	40	"
Veit	1 "	"	37.2	"
Geisler[21]	1 "	"	50	"
Krunkenberg	1 "	"	47	"
Gessner	1 "	"	34	"
Norris	1 "	"	48	"

The average rate, derived from a combination of these observations, is 1 sarcoma to 41.8 carcinomata.

The relative frequency of sarcoma and myoma found by various investigators is shown in the following table, and is of importance because of the frequency with which certain varieties of sarcoma simulate myoma.

Earlier studies showed a much greater frequency of sarcomata, as has already been mentioned. This greater frequency of sarcomata has, however, been

Evans.....	72	sarcomata	among	4,000	myomata,	or	1.8	per cent
Geist[15].....	22	"	"	540	"	"	4.07	" "
Kelly and Cullen[16] ...	17	"	"	1,400	"	"	1.2	" "
Franz[17]	9	"	"	1,390	"	"	0.64	" "
Masson[18].....	44	"	"	4,322	"	"	1	" "
McDonald[19]..	7	"	"	700	"	"	1	" "
*Vogt[20].....	8	"	"	1,216	"	"	0.65	" "
Total....	179	"	"	13,568	"	"	1.31	" "

* This material is from the Gynecological Division of the Hospital of the University of Pennsylvania.

proved incorrect as far as the general average is concerned, and was probably the result of some error in histological diagnosis. This is particularly likely, as a large proportion of myomata undergo some form of benign degeneration and, if such tumors are carefully searched, extremely cellular areas are often found which may be readily diagnosed as sarcoma by the inexperienced pathologist.

Sarcoma of the uterus occurs in the following forms: (a) cervical; (b) sarcoma of the corporeal endometrium or (c) of the myometrium; and (d) sarcomatous change in myomata.

Cervical sarcoma has been previously referred to. Sarcoma is four or five times as frequent in the body of the uterus as in the cervix, and in this respect differs from carcinoma in which tumor the relative proportion is reversed. Gessner [22] found the tumors to be in the body of the uterus in 88 per cent of cases of sarcoma, Meyer [23] and Piquand [24] set this percentage at 96.7 and 82.5 respectively.

Sarcoma of the Corporeal Endometrium.—This is a rare form of sarcoma, and may occur at any age. It is relatively frequent among children. Parity apparently has no bearing upon its etiology. Graves [25] states that 25 per cent of the recorded cases developed in nulliparæ. Wilms (quoted by Graves) believes that the grapelike tumors are of embryologic origin, developing from rests of the Wolffian duct. Other authorities claim that they spring from the blood-vessels, but such a tumor would probably be an endothelioma or a perithelioma. However, the majority of these sarcomata probably originate in the endometrial stroma. The growths may be inverting or everting, or both.

As a result of edema, the polypoid tumors may suggest hydatidiform moles. The sarcoma botryoides or grapelike sarcoma is of this variety. These tumors are extremely malignant and are commonly observed in children. Tumors of this type are white, gray, pinkish, or red in color, extremely vascular, friable, and on section are smooth, soft, and semi-translucent. They are rapid in growth, sometimes filling the uterine cavity, and often are observed to extend from the cervix or even to present beyond the vulva.

A sarcoma developing from the mucosa may be diffuse or, less frequently, circumscribed. It commonly originates in the fundus and later tends to

involve all of the corporeal endothelium, often sparing that of the cervical canal. This type is more common in the adult. The uterus is enlarged, the endometrium polypoid in appearance. The tumor is extremely vascular, homogeneous on section, and can be seen penetrating the myometrium from which it can be easily distinguished. Necrotic areas may be present.

The circumscribed type develops as one or several more or less definitely limited tumors, which may grow inward in a polyplike manner or outward into or through the uterine wall.

Endometrial sarcoma may penetrate the myometrium and serosa, and invade the intraperitoneal viscera. Large intraperitoneal growths have been observed. Pyometra and hematometra sometimes develop.

Histologically these tumors are generally round-celled but spindle- and giant-cells may be found. Tumors composed largely of decidual like cells have been observed, and have been attributed by Meyer to changes incident to menstruation. They are extremely vascular, and contain little intercellular stroma.

The chief symptoms are bleeding and discharge. The bleeding is irregular in periodicity, duration, and amount, and increases rapidly. The discharge is thin, watery, irritating and—especially in the later

stages—malodorous. It is extremely profuse in many cases, and often blood-stained.

Later in the disease, loss of weight and strength, anemia, cachexia, and evidence of metastasis are obvious. Pelvic examination may show the tumor to protrude through the cervical canal, or even beyond the vulva. The uterus is enlarged.

In early cases the Clark test (see p. 98) and diagnostic curettage or biopsy are valuable in establishing the diagnosis. Bleeding, or the presence of a cervical or uterine tumor, should always arouse suspicion when occurring in children prior to the onset of menstruation.

These tumors possess a high degree of malignancy, are of rapid growth, and produce early and often distant metastases. The prognosis is bad except in the extremely early cases. As in fundal carcinoma, the integrity of the myometrium is the most important prognostic factor.

Radical panhysterectomy and bilateral salpingo-oöphorectomy, followed by deep X-ray irradiation, should be employed for the early cases. Intra-uterine irradiation with radium, combined with deep X-ray therapy, should be tried in the more advanced cases. In case a diagnostic curettage is performed, intra-uterine treatment with radium should accompany the operation. The irradiation is given

to inhibit the growth and to prevent transtubal dissemination.

The Blair Bell lead treatment has been employed with success in some uterine sarcomata, and offers some hope even in desperate cases. It is, however, not suitable in every instance, and in its present stage of development, cannot be compared with either operation or irradiation.

Blair Bell's most recent publication shows the effect of his treatment upon various types of malignant tumor in different parts of the body.[26] His report covers the period between November 20, 1920, and November 9, 1928, and gives the following data on results of the treatment:

Total number of cases treated	566
Died of the disease before treatment could be completed	359
(a) Received less than 0.25 gm. of lead, 198	
(b) Received more than 0.25 gm., but less than 0.5 gm. of lead, 161	
Died of disease after treatment was concluded	77
Died of intercurrent affections while under treatment	7
Died as a result of extensive destruction of tissue	5
Received complete course of treatment (two years)	22
Too recent for results to be estimated	31
Believed cured but died from other conditions	2
Disease completely arrested	12
Believed cured and treatment stopped	51

In this paper Bell emphasizes that the majority of these were of the so-called hopelessly advanced stage.

Sarcomata of the Myometrium.—Some authorities believe that these tumors are not primary, but are always degenerations of a myoma. It is probable,

however, that the tumor may spring from normal myometrium as well as from myomata. The latter are often easily recognizable. The author has observed two tumors which presented all the characteristics of primary growths, and also a number of others which were probably primary.

Sarcomata of the myometrium may be single or multiple. Macroscopically they appear as more or less circumscribed, whitish, pinkish, or grayish neoplasms. They may possess a well-defined capsule, but this is, as a rule, less developed than in myomata. The sarcoma may often be observed growing into the capsule, which as a result is irregular in thickness. On section the tumor may be soft, semi-translucent and friable, or more firm and fibrous, depending upon the type of cell predominating. The round-cell usually is found in the former type, and the spindle-cell in the latter. Giant-celled and mixed forms have also been observed.

The prognosis depends upon the character and advancement of the tumor. The more embryonal types, *e.g.* the round-celled, are highly malignant. The spindle-celled form is slower in growth and gives a more favorable prognosis.

These tumors may occur at any age, but are most frequent after forty and, unlike myomata, are prone to develop after the establishment of the menopause. The symptoms vary with the situation, size,

and stage of development of the tumors. Hemorrhage, discharge, and pressure symptoms are among the most frequent.

The embryonal varieties may be often recognized clinically by their gross appearance, while the spindle-celled form can be diagnosed with certainty only by microscopic examination.

Sarcomata of the uterine walls are often mistaken for myomata. Their rapid growth is one of the chief differentiating points. A tumor, apparently a myoma, which exhibits definite growth after the establishment of the menopause and especially if it develops after this period, is more likely to be a sarcoma than a myoma. Sarcomata differ from myomata in that they are as frequent in the white as in the negro race.

The prognosis depends largely upon the variety of the tumor. The round-celled type is highly malignant and produces moderately early metastases, while the spindle-celled form is more favorable. After operation probably about 33 to 50 per cent of patients with sarcoma of the uterine wall survive five years.

Radical panhysterectomy and bilateral salpingo-oöphorectomy, followed by deep X-ray irradiation, is the method of choice. Intrauterine radium treatment, combined with deep X-ray therapy, may be employed in the inoperable cases.

Sarcomatous Change in Uterine Myomata.—"Malignant myoma," "recurrent fibroid," and "malignant leimyoma" are terms occasionally used to denote this condition. The frequency of sarcomatous change, often termed "degeneration," has been previously referred to. It is rare, and the tendency among inexperienced pathologists is to overestimate rather than underestimate its rate of occurrence.

In our own laboratory, where all myomata are subjected to a rigid histologic study, sarcomatous change was observed infrequently. Of 600 supposed myomata, treated by us with irradiation, none has subsequently developed symptoms indicating a sarcomatous change. These cases were carefully selected, and no tumors of rapid growth or otherwise exhibiting evidences of malignancy were treated in this manner. Most of the patients received only 1,200 mg.h. or less of intrauterine radium irradiation, and it seems highly improbable that this would have been curative in the presence of sarcomatous change.

Corsceden and Stout [27] state that during the last thirty years, many thousands of cases of fibromyoma of the uterus have been treated by irradiation. During the same period there were reported four cases of sarcoma of the uterus in fibromyoma which were inadvertently treated by this method and recog-

nized by a continuance of growth after the radiotherapy.

The histogenesis of sarcomatous change is uncertain. The theory of a metaplasia of muscle-cells into sarcomatous tissue, which was formerly universally accepted, has been questioned by Meyer [28] and others.

Lynch and Maxwell [29] state that many theories have been advanced regarding the pathogenesis of these tumors, but that these theories may be grouped under the following three headings: (1) those ascribing the sarcomatous change to proliferation of the cells of the vessel walls; (2) those blaming it on proliferation of the cells of the intermuscular fibrous tissue; (3) those claiming it to be caused by a transformation of smooth muscle-fibers.

The theory that these tumors are the result of a metaplasia of muscular to sarcomatous tissue is probably the one most generally, although by no means universally, accepted.

The sarcomatous change may occur in any part of the myoma, but is more frequent near the center. When multiple myomata are present, only one of them is usually the seat of sarcomatous change.

On section the sarcomatous tissue is smoother, softer, more vascular, and more homogeneous than the myomatous tissue. It may be white, yellowish, pinkish, or grayish in color, and in the larger tu-

mors often contains small cystic spaces filled with turbid, blood-stained, or clear fluid. Hemorrhagic areas are of frequent occurrence. If the sarcoma is situated near the capsule, irregularity in the thickness of this structure can often be macroscopically detected when the malignant process has extended into it. This encroachment or eating into the capsule is characteristic of sarcoma, and is a valuable sign in the recognition of this disease.

These tumors are rarely recognized clinically, are frequently overlooked macroscopically, and can be positively diagnosed only by histologic examination. A not uncommon history is that a supravaginal hysteromyomectomy has been performed, and a recurrence develops in the stump. The pathologist, who may have sectioned only one of the myomata and pronounced it benign, then sections the old specimen at the point of amputation and finds a sarcoma to be present.

Sarcomatous change may occur in any type of myoma. It is said to be more frequent in old myomata, and may be found in association with any of the benign degenerations. Histologically these tumors may be spindle- or round-celled or mixed-celled in type, the first-mentioned being the most common. Occasional giant-cells may be present.

There are no characteristic symptoms. The history and the pelvic findings are suggestive of uter-

ine myoma. Rapidity of growth, especially when following the menopause, is a symptom of sarcoma. In the later stages loss of weight, cachexia, evidences of metastases, and other signs common to advanced malignant tumors are present. Pressure upon the ureters may result in the development of renal symptoms. One case has come under the observation of the author in which a sarcomatous nodule perforated the vesical wall and, upon cystoscopic examination, could be seen projecting into the cavity of the bladder.

Metastases vary with the type of growth. In the more malignant forms they occur through the blood-stream, and are frequently widespread. Pulmonary, hepatic, intestinal, omental, renal and osseous metastases have been recorded. The ovaries and retroperitoneal glands may be invaded. Widespread metastases are more commonly encountered with endometrial and primary myometrial sarcoma than in the type under discussion. In sarcomatous change in myomata, especially when of the spindle-celled variety, metastasis is late and usually results in local recurrences. The metastatic lesion is usually of a type similar to the original tumor.

The prognosis largely depends upon the type of sarcoma present, but should in any event be guarded. The spindle-celled type is the least malignant. Death may result from uremia, cachexia,

sepsis, recurrent hemorrhages, or some intercurrent disease.

Panhysterectomy and bilateral salpingo-oöphorectomy is the treatment of choice. Deep X-ray therapy should be employed postoperatively in the more malignant varieties. Intrauterine radium irradiations and X-ray therapy may be employed for palliative purposes in the inoperable stages.

Supravaginal hysteromyomectomy is a common operation. Every specimen so removed should be carefully examined before closing the abdomen, and, if necessary, a frozen section made. If specimens are not cut into, carefully inspected, and occasionally submitted for immediate frozen section diagnosis, a cervix which has already been invaded by the sarcoma may be left behind. In the laboratory a rigid macroscopic and microscopic examination of every supposed myoma should be insisted upon and, if any doubt exists, sections from the point of amputation should also be examined.

Special Types of Sarcoma.—Alveolar types have been observed. Meyer [30] has described a tumor containing large and small alveolar arranged in a radiating manner.

Angiosarcomata are occasionally seen. The true angiosarcoma is composed of sarcomatous tissue and newly formed blood-vessels. Perivascular arrangement in various degrees may be present, and

constitutes some forms of the so-called alveolar type of tumor.

A lipomyosarcoma has been reported by Sitzenfrey.[31]

Adenofibromyxochondrosarcoma or rhabdomyosarcoma, and other sarcomata containing various structures, have been observed. Many of these unusual tumors have originated in the cervix. Gottschalk [32] describes a perithelial and cylindromatous tumor which he attributes to nutritional conditions.

Melanosarcoma with cerebral metastases has been reported by Williams.[33] Many of the cases formerly considered as melanosarcoma would now be classed as melanoma.

Schlagenhaufer [34] has described a lymphosarcoma. In addition to these, sarcomata have been found combined with adult mesodermal tissue, such as bone, cartilage, and striped muscle.

Peterson [35] has reviewed the histogenesis of fifty cases of embryonal uterine tumors secured from the literature, which had been reported under various names indicative of their constituents (*e.g.* lipomyosarcoma, myxochondroma, and rhabdomyoma). Of contained mesoblastic tissue, cartilage was present in 64 per cent, and either smooth or striated muscle in a similar proportion of cases. These tumors were found in both cervix and fundus, but more frequently in the latter. No age appeared

immune, the patients being from two to seventy-five years of age. In Peterson's series, one half of the patients were over fifty. Parity apparently played no predisposing part in the series. Recurrences were generally local.

Carcinosarcoma.—Combinations of carcinoma and sarcoma have been observed in the same uterus, and one such case has been recorded by Outerbridge [36] in our own laboratory. At the time of his report Outerbridge collected twenty-seven additional cases from the literature. An overlap of the two tumors may occur, and von Hansemann [37] believes that the stroma of the carcinoma may become sarcomatous. In the histologic diagnosis of cases of supposed combined sarcoma and carcinoma, considerable judgment must be exercised, for, whereas there is no doubt that such combinations occur, they are extremely rare. Furthermore, both these tumors are prone to exhibit different histologic pictures in different portions of the growth, some sarcomata present more than superficial resemblances to carcinoma, and *vice versa.* It is a significant fact that the metastases from many of the recorded cases were clearly either all sarcomatous or all carcinomatous. In Kubinyi's case the metastases to the bones were all sarcomatous and those to the soft parts all carcinomatous. For literature up to 1922 see Frank [38] and Kubinyi.[39]

Frank has collected the records of a number of remarkable cases. Albrecht [40] observed a polypoid sarcoma which had caused an inversion of the uterus upon the endometrium of which a carcinoma had developed. Meyer [30] described an adenocarcinoma combined with a polymorphous spindle-celled sarcoma.

In our own laboratory we have a specimen representing a squamous-celled carcinoma of the cervix and a spindle-celled sarcoma of the fundus, and another specimen containing a small round-celled sarcoma in one horn of a bicornuate uterus, which was the seat of an adenocarcinoma of the fundus in the opposite horn, and a large benign endometrial polyp.

ENDOTHELIOMA

This is a rare tumor, and some authorities even question its existence. Many of the recorded cases are probably sarcomatous. Undoubtedly, the more thoroughly these specimens are studied, the fewer endotheliomata and the more sarcomata are found.

Ewing [41] believes that angiosarcoma, embryonal epithelioma, and atypical forms of ordinary epithelioma may be readily mistaken for endothelioma. In 1916 Dorland [42] collected the reports of thirty cases of endothelioma from the literature, sixteen of which were cervical in origin.

Endotheliomata vary markedly in malignancy; indeed, Meyer [30] in a valuable contribution containing a review of the literature, has described a benign form composed largely of spindle-cells. In 1923 Murphy [43] reviewed the literature pertaining to endothelioma of the uterus, and collected the reports of forty-eight cases, to which he added one of his own. He found that the majority of these tumors were cervical in origin and when fundal in location, often developed upon a fibromyoma. Whether they are cervical or fundal, the endotheliomata are not recognizable without the aid of the microscope. An endothelioma situated in the fundus usually presents the appearance of a sarcoma or myoma, while the cervical tumors are usually mistaken for carcinomata.

Various criteria have been given for the histologic diagnosis of endothelioma. According to Meyer [30] the presence of sarcomatous- and adenomatous-like tissue originating from the same type of cells, or tumors which present a structure similar to sarcoma or carcinoma, but which actually are neither one nor the other, are probably endothelioma. Ewing,[41] on the other hand, believes that the diagnosis of endothelioma is frequently carelessly made, and that it should be possible to definitely trace the origin of the tumor to the normal endothelium—an opinion shared by the author.

Dorland's cases occurred between the ages of eighteen and sixty-eight years, the greatest number occurring about the menopause. Murphy found the average age to be forty-four, the oldest patient seventy, and the youngest eighteen. About one-fourth of the patients were multiparous. Irregular bleeding, usually metrorrhagic in type, was present in 83 per cent of the cases. Pain was a marked feature in less than one-third of the cases.

Discharge similar to that produced by carcinoma is of frequent occurrence. In the later stages anemia, cachexia, loss of strength and weight, and other manifestations of malignancy develop. Like sarcoma, endothelioma varies markedly in degree of malignancy, the more embryonal tumors being highly malignant, growing rapidly, and producing early and sometimes widespread metastases. The differentiated types, especially those developing upon myomata, resemble in their course the spindle-celled sarcomata which develop in myomata. A considerable proportion of the endotheliomata is of comparatively low-grade malignancy, as shown by Murphy and Lockyer.

Altogether too few cases have been studied in regard to end-results, to allow any definite conclusions. The treatment usually adopted is similar to that employed for sarcoma.

PERITHELIOMA

Perithelioma and periendothelioma are clinically and macroscopically quite similar to sarcoma. Whereas the endotheliomata take their origin from the endothelium which lines the blood-vessels and lymph-spaces, the peritheliomata originate from the endothelial layer surrounding the adventitia of the blood-vessels.

Both perithelioma and true endothelioma are mesoblastic neoplasms, and are therefore closely akin to sarcoma. Ewing[41] states that in certain rapidly growing and atypical epitheliomas of the cervix the cells become arranged about blood-vessels, producing a peritheliomatous structure. He quotes Hansen as describing an intravascular hemangioendothelioma, and further adds that the existence in the uterus of a tumor of vasoformative cells is uncertain. The symptoms, prognosis, and treatment are generally similar to those of sarcoma.

SYMPATHOMA

Under this heading Graves[25] quotes Limeland and Durante, who described a uterine tumor microscopically similar to the argentaffine neoplasms of the sympathetic nervous system, of which the carcinoid new-growths of the vermiform appendix are representatives. Limeland and Durante believe

their tumor to have originated from the nervous system of the uterus, rather than to be an ectopic paraganglioma.

LIPOMA

As the name indicates, lipomata are tumors containing adipose tissue. They may be composed of fat entirely or only partially. They should not be confused with myomata or other tumors undergoing fatty degeneration.

True lipomata of the uterus are rare tumors. As in many uterine and ovarian new-growths the genesis is uncertain, but the predominant opinion is that they are embryonal in origin, and represent neoplastic development from mesoblastic rests of the Wolffian duct. Meyer attributes their origin to parametrial fat which, during embryonal development, becomes included in the Wolffian and Müllerian ducts. Metaplasia from connective tissue, and ingrowth of true fat along the course of vessels and nerves, are, according to Graves, other theories regarding their development.

True lipomata, lipomyomata, lipofibromata, and liposarcomata have been described. Lipomata are most commonly situated in the fundus, and often at the tubal angles. They vary markedly in size and are usually sessile, although polypoid growths have

been observed. Ellis [44] reported fourteen cases, ten of which were fundal and four cervical in location.

Pure lipomata are lobulated, and resemble the lipomata occurring in other parts of the body. They are benign, but may develop in conjunction with sarcoma or may undergo sarcomatous change. For literature, see Frank,[38] Seydel [45] and Elkin and Haythorn.[46] Rawls [47] reported a lipoma of the broad ligament, and Lockyer [48] recorded a case of his own and collected seven others from the literature.

For a further study of the subject of mixed tumors of the uterus, which includes many complex heterologous neoplasms, the reader is referred to Frank's valuable review of the literature in 1922.[38]

REFERENCES

[1] Lebert, H., *Physiologie pathologique*, 1843, vol. iii, 155.
[2] Mayer, C., *Verhandl. der Gesellschaft f. Geb.*, Berlin, 1860, 12-19.
[3] Paget, J., *Lectures on Surg. Path.*, London, 1863, p. 575.
[4] *Virchow's Arch.*, 1865.
[5] *Veit's Handbuch d. Gyn.*, 1867.
[6] Gusserow, *Arch. f. Gyn.*, 1870.
[7] Hegar, A., *Arch. f. Gyn.* 1871, vol. ii, p. 29.
[8] Lockyer, S., *Practice of Surgery*, Hagerstown, Md., 1928, vol. xi, chap. 19.
[9] Pfannenstiel, J., *Arch. f. Path. Anat. etc.*, Berlin, 1892, 127, p. 305.
[10] von Kalden, C., *Beitrage z. path. Anat. u.z. allg. Path.*, Jena, 1893, vol. xiv, p. 174.
[11] Williams, J. W., *Amer. Jour. Obst. & Gyn.*, New York, 1894, vol. xxix, p. 721.
[12] Meyer, R., in *Veit's Handbuch d. Gyn.*, 1908, vol. iii.

[13] Gessner, A., *Handbuch d. Gyn.*, 3rd ed., 1908, 2, 869.
[14] Vogt, M. E., *Amer. Jour. Obst. & Gyn.*, v, p. 523.
[15] Geist, L., *Jour. Amer. Med. Assn.*, 1920, vol. lxxiv, p. 752.
[16] Kelly, H. A., and Cullen, T. S., *Myoma of the Uterus*, Philadelphia and London, 1909.
[17] Franz, K., *Arch. f. Gynäk.*, 1917, vol. cvii, p. 129.
[18] Masson, J. C., *Amer. Jour. Obst. & Gyn.*, 1923, vol. v, p. 345.
[19] McDonald, E., *Jour. Amer. Med. Assn.*, 1904, vol. xlii, p. 1349.
[20] Vogt, M. E., *Amer. Jour. Obst. & Gyn.*, 1923, vol. v, p. 523.
[21] Geisler, A., *Ueber Sarkoma uteri., Diss.*, Breslau, 1892.
[22] Gessner, *Veit's Handbuch f. Gynäk.*, 1st. ed.
[23] Meyer, *Veit's Handbuch. f. Gynäk.*, 1st ed.
[24] Piquand, *Thèse de Paris*, 1905.
[25] Graves, W. P., *Gynecology*, Philadelphia and London, 1928, p. 367.
[26] Bell, W. Blair: *Brit. Med. Jour.*, 1929, March 9, p. 431.
[27] Corsceden, J. A., and Stout, A. P., *Amer. Jour. Roentgenol.* 1929, vol. xxi, p. 155.
[28] Meyer, R., Lubarsch-Ostertag Ergebn., 1894, vol. ii, p. 518.
[29] Lynch, F. W., and Maxwell, A. F., *Pelvic Neoplasms*, New York and London, 1922, p. 289.
[30] Meyer, R., *Veit's Handbuch d. Gyn.*, vol. i, c. 32.
[31] Sitzenfrey, *Ztschr. f. Geburtsh. u. Gynäk.*, 1910, vol. lxvii, p. 32.
[32] Gottschalk, *Ztschr. f. Geburtsh. u. Gynäk.*, 1903, no. 40.
[33] Williams, J. W., *Prager Ztschr. f. Heilk.*, 1894, vol. xv, p. 141.
[34] Schlagenhaufer, *Arch. f. Gynäk.*, 1912, vol. xcv, p. 1.
[35] Peterson, A. J., *Jour. Lab. and Clin. Med.*, 1923, vol. viii, p. 369.
[36] Outerbridge, G. W., *Amer. Jour. Obst. & Gyn.*, 1913, vol. lxxv, p. 575.
[37] Von Hansemann, *Die mikroskopische Diagnosis der Bösartigen Geschwülste*, Berlin.
[38] Frank, R. T., *Gynecological Pathology*, New York and London, 1922.
[39] Kubinyi, *Arch. f. Gynäk.*, 1912, vol. xcvi, p. 405.
[40] Albrecht, H., *Frankf. Ztschr. f. Path.*, 1908, vol. ii, no. 1.
[41] Ewing, *Neoplastic Diseases*, Philadelphia and London, 1919.
[42] Dorland, W. A. N., *Surg., Gyn. & Obst.*, 1916, vol. xxiii, p. 576.

[43] Murphy, D. P., *Surg., Gyn., & Obst.*, 1923, vol. xxxvii, p. 24.
[44] Ellis, A. G., *Surg., Gyn., & Obst.*, 1906, vol. iii, p. 658.
[45] Seydel, *Ztschr. f. Geburtsh. u. Gynäk.*, 1903, vol. l, p. 2.
[46] Elkin, C. W. W., and Haythorn, S. R., *Surg., Gyn., & Obst.*, 1917, vol. xxv, p. 72.
[47] Rawls, R. M., *Amer. Jour. Obst. & Gyn.*, 1926, vol. xi, p. 305.
[48] Lockyer, C., *Proc. Roy. Soc. Med.*, London, 1918-19, p. 195.

CHAPTER VI

TUMORS OF THE CHORION

NO SATISFACTORY classification of tumors of the chorion has as yet been made. These tumors vary from entirely benign new growths to some which are among the most malignant of the known neoplasms. Various efforts have been made to formulate a histologic classification which will definitely define the grade of malignancy. Attempts at correlation of the histologic characteristics with the grade of malignancy have not, however, been entirely satisfactory. In 1903 Teacher [1] suggested the classification of chorionic tumors into the following divisions: (1) simple benign hydatidiform moles; (2) malignant or destructive hydatidiform moles—*i.e.*, moles which exhibit a marked proliferation of the trophoblast with an unusual tendency for invasion and producing metastases; (3) chorioepithelioma possessing no chorionic villi; and (4) an intermediate group, mainly composed of chorioepithelioma, but showing some evidence of villi. Novak classifies as (1) chorioma benignum or hydatidiform mole and (2) chorioma malignum or chorioepithelioma. Ewing [2] divides chorioepitheli-

oma into (1) chorioadeno destruens, destructive placental mole; (2) choriocarcinoma; and (3) syncytioma and syncytial endometritis. Geist,[3] Wolfe,[4] and others have also suggested classifications.

HYDATIDIFORM MOLE

Hydatidiform mole is a condition in which the chorionic villi, especially the terminal ends, are converted into oedematous cystic vesicles containing fluid. These are pedunculated and vary in size, some being larger than a grape.

Virchow attributed these to a myxomatous change and named the tumor myxoma chorii. Bremser[5] states that the name hydatidiform came about because of the close resemblance between these tumors and echinococcus cysts. In 1837 Madame Boivin[6] described this lesion as being of chorionic origin, and in 1895 Marchand demonstrated the ectodermal and neoplastic character of the tumor.

Etiology.—Little is known of the etiology of this tumor. In a series of 394 cases, Findley[7] found the age distribution to be as follows:

Below 15 years	3
Between 15 and 25 "	111
" 25 " 35 "	143
" 35 " 45 "	84
" 45 " 50 "	36
" 50 " 55 "	17

The disease is most frequent during the child-bearing period, although Molitor[8] recorded the

history of a case which occurred in a girl of nine years of age. Hydatidiform moles are more common in multiparæ than in primiparæ. Essen-Moller[9] has recorded the history of a remarkable case in which a woman passed eighteen moles in a period of nine years. Multiple molar pregnancy is infrequent. Findley[7] found seven instances of this condition among 500 cases. Essen-Moller and Findley fix the frequency of hydatidiform formation as once in 2,000 or 3,000 gestations. This is the proportion of moles, most of which can be recognized macroscopically. There is reason to believe that milder forms of the disease probably occur more frequently, and that this is a not uncommon cause of abortion. The fetuses accompanying molar pregnancies are generally dead, and often not discoverable. Living fetuses have been reported by Jonas,[10] Broadhead[11] and others have recorded twin pregnancies in which a mole was present in one and the other was viable and normal.

Pathology.—A typical specimen can hardly be mistaken. The entire placenta appears transformed into a mass of grapelike cysts, which vary from a few millimeters to four or five centimeters in diameter. Many of these possess gracile pedicles, some of which are of considerable length. The cysts are tense, oval, or round. Upon section or puncture

a few drops of clear, turbid, or sometimes blood-stained fluid appears. In other specimens only a portion of the placenta is involved. Specimens are also

FIG. 14.—*Hydatidiform Mole.* The characteristic grapelike vesicles are unmistakable.

seen in which one twin is contained in a separate amniotic sac and the other is represented by a vesicular mole. In the majority of cases, especially after expulsion, neither sac nor fetus is demonstrable. On section the vesicles are seen to be composed

of a cyst wall of moderate density and to contain a small amount of clear or turbid fluid.

Histologically.—The villi are enlarged and swollen, but often retain their villous-like shape. The normal covering may be preserved or altered. Proliferation of the Langhans cells and an increase in the number and size of syncytial buds, together with a general increase in the ectodermal tissue, are found. The stroma is composed of embryonal connective tissue, is oedematous, and stains poorly. Hyaline degeneration is not infrequent, and calcareous areas have been observed. The blood vessels are scanty. The chief histologic characteristics are the great enlargement of the villi, the oedema of the stroma, proliferation of the enveloping cells, and avascularity.

Ovaries.—In about 50 per cent of cases of hydatidiform mole the ovaries are the seat of lutein cysts. The cysts are bilateral, multilocular, and thin walled, containing thin, turbid or clear watery or yellowish fluid, which in some instances is blood-tinged. The cystic ovaries vary in size and may be as large as a man's head. Cystic ovaries the size of an orange, or somewhat smaller, are more frequent.

Histologically the cysts are lined with lutein cells, of which two or more layers are present. These cells present the typical appearance, but are often altered as a result of intracystic pressure. Ac-

cording to Frank [12] a diffuse lutein cell hyperplasia in the stroma of the ovary, to a degree even more marked than in normal pregnancy, is common, although not always present. Pick [13] believes that the placental change is secondary to the ovarian and that the latter is the etiologic factor. Bilateral oöphorectomy has frequently been performed in these cases. Spontaneous retrogression of the lutein cysts nearly always occurs within a few months, after expulsion of the mole and thereafter the ovaries apparently function normally and regain their normal size. Oöphorectomy should by no means be resorted to until it can be determined that regression of the cysts will not occur. Fruhinsholz [14] reports two cases in which regression of the cysts followed curettage.

Classification.—Many authorities divide hydatidiform moles into two groups, the benign and the malignant; but this is a questionable classification. There are many reasons to believe that all moles are benign and that the so-called malignant variety is merely one in which this change has occurred and is analogous to the carcinomatous change which may occur in a benign ovarian cyst and to the sarcomatous change which may develop in a uterine myoma. For this reason the so-called malignant variety will be considered under the heading of chorioepithelioma.

Symptoms.—The patient usually believes herself pregnant. Amenorrhea is present for from two to three months or more. Bleeding may develop at any time or may be absent. Bleeding is usually irregular, bright, and may be constant or occur at intervals, with a general tendency to become more profuse despite treatment. Between the periods of bleeding there may be a discharge of dark brown or pinkish gelatinous fluid and portions of the mole may be passed. These small, grapelike vesicular cysts are pathognomonic. Toxemia, hyperemesis and anemia often out of proportion to the amount of hemorrhage which has been present are frequent. In other cases the first intimation of the disease is bleeding, accompanied by cramplike pain in the lower abdomen, which is often mistaken for a threatened abortion. These symptoms are followed by the expulsion of the mole.

Expulsion of the mole generally occurs before the sixth month and usually between the third and fifth months. Less than 5 per cent of the cases go to term.

Examination shows the usual signs of pregnancy. An additional fact of especial diagnostic significance is that the uterus is larger than it should be according to the advancement of the pregnancy. The bilateral cystic enlargement of the ovaries is demonstrable in one-third to one-half the cases, and may

be the first thing to call the attention of the physician to the condition. Following expulsion of the mole, convalescence is usually uneventful. Portions of the mole may be retained and result in hemorrhage which requires its removal by curettage or other means. This is analogous to an incomplete abortion. In rare instances the mole may be retained for months. In the event of a twin pregnancy, if one is a molar and the other a normal, both are usually expelled prematurely. Histories of a few cases have been recorded in which the mole was expelled while the other pregnancy had gone to term and resulted in a viable infant.

Diagnosis.—The symptoms of a threatened abortion, and a rapid enlargement of the uterus to a size out of proportion to the calculated advancement of the pregnancy, are suggestive of a molar pregnancy.

Hydatidiform moles must be differentiated from abortion resulting from other causes, neoplasms such as carcinoma and myoma, ovarian tumors, premature separation of the placenta and placenta prævia, and other varieties of lesions causing hemorrhage during pregnancy.

Treatment.—A curettage and histologic examination of the material secured should be performed. At the time of the curettage the cervix should be widely dilated and the inner surface of

the uterine cavity should be palpated. If evidences of definite erosion or invasion of the myometrium are palpable, or if the histologic examination shows malignancy, a hysterectomy is indicated. If, despite the fact that these indications of malignancy are absent, bleeding recurs within a week or ten days, a second curettage is indicated. Should further portions of the mole be found at this time, it is generally an indication that the first operation has been incomplete. Should the second curettage fail to check the hemorrhage, the probabilities are that malignancy is present, upon which an abdominal hysterectomy is indicated. In dealing with hydatidiform mole the probabilities of malignant change should be constantly borne in mind. Recurrent hemorrhages, anemia, and toxemia are all suggestive of this process.

The histologic appearance of the material secured at the first curettage is, in some senses, a guide. In some cases the curettings definitely show a malignant tumor to be present, and under such circumstances hysterectomy should be resorted to without delay. Unfortunately, in many cases histologic examination is of no great value, and, unless definite malignancy can be proved by the use of the microscope, it is preferable to be guided by the clinical evidence. Schumann [15] advocates an abdominal hysterotomy for exploratory purposes in

all cases and in addition hysterectomy if the former shows evidence of malignancy. In women past forty-five years of age, or in those border line cases which present some evidences of malignancy but which are by no means definite, this treatment has much to recommend it. Any trauma, such as a curettage or even firm palpation, is prone to disseminate chorioepithelioma. The cells of the chorioepithelioma still retain their trophoblastic tendencies of penetrating blood-vessels, and metastatic emboli are commonly present in the sinuses. Trauma of any sort is therefore likely to result in widespread dissemination. As a routine procedure, however, abdominal hysterotomy is not generally accepted as the most appropriate treatment and the method previously indicated is preferable.

The mortality from hydatiform mole varies quite markedly in different series, ranging from five to twenty-five per cent. Infection, malignant change, hemorrhage, and toxemia account for most of the deaths.

Bland [16] believes that nearly 10 per cent of patients suffering from hydatid moles die either from hemorrhage or from chorioepithelioma. He reports ten cases of hydatid mole, six of whom subsequently developed chorioepithelioma. The incidence of malignancy in this series is unusually high. According

to Greenhill [17] not more than 2 or 3 per cent of moles are followed by chorioepithelioma.

The frequency with which malignant change develops in apparently benign moles is an important point in determining the appropriate treatment and is a phase that deserves further study. Some investigators have found malignant change in nearly one third of their cases. Teacher [1] believes that the frequency of its occurrence is less than 5 per cent, while Novak, estimating upon histologic and clinical evidence, places the proportion at less than 1 per cent. It is probable that their differences are largely accounted for by the difficulties surrounding the histologic recognition of this type of malignancy. The writer has seen nine cases of definite hydatidiform mole, all recognizable without the aid of the microscope, and during this time has observed two cases of chorioepithelioma, a proportion of 22 per cent. During the same period lesser degrees of hydatidiform mole development have been encountered many times in the routine examination of material secured following curettage for abortion, and in none of these latter instances did chorioepithelioma develop.

CHORIOEPITHELIOMA

Chorioepithelioma is the term applied to a tumor having its origin in the chorionic epithelium which

may occur after abortion, miscarriage, premature labor, labor at term, or years after the expulsion of the products of conception. The tumor or group of tumors vary markedly in their histologic and clinical characters. Some of them are highly malignant, causing early and widespread metastases, while others undergo disappearance spontaneously or following operations involving incomplete removal such as curettage.

Historic.—In 1867 Vokmann [18] clearly described the clinical picture of this tumor. Ten years later Chairi described three cases, all of which followed childbirth, which he believed to be atypical carcinomata. In 1893 Sanger [19] reported the result of his studies of this tumor, defining it as a clinical entity. He, however, considered it to be of connective tissue origin, and gave to it the name sarcoma uteri deciduocellulare. It was not until 1895, as a result of Marchand's studies, that the epithelial character of the tumor, as well as its exclusively chorionic origin, was generally recognized.

Etiology.—One-third to one-half of the chorioepitheliomata are preceded by clinically recognized hydatidiform moles. Five to 10 per cent of the well-defined examples of the latter tumors are followed by chorioepitheliomata. Sunde [20] found the figure to be 5 per cent, while Hitschmann and Cristofoletti [21] in 200 cases of moles, found that

7.5 per cent were followed by chorioepithelioma. Findley [7] found that malignancy developed in 26.5 per cent of his collected cases. Findley's 26.5 per cent represents a proportion considerably higher than that generally observed by other investigators. Chorioepitheliomata are more frequent in multiparæ. Teacher,[1] in his series of 188 cases collected from the literature, found that 37.8 per cent of the cases occurred in women who had been pregnant five or more times, while 28.24 per cent followed the second or third pregnancy. Chorioepitheliomata are more common in women past forty, although younger women are by no means immune.

Pathology.—Chorioadenoma destruans or destructive placental mole (Ewing) is a tumor yielding a characteristic gross appearance. The uterus is enlarged, sometimes reaching the size of a two months' pregnancy. The myometrium is thickened and multiple or single areas of erosion are present. In advanced cases nodules may be visible under the serosa, and extensions into the broad ligament, tube, cervix, and vagina may occur. The neoplasm may perforate the entire thickness of the uterine wall and result in an intraperitoneal hemorrhage, or peritonitis. The veins are engorged and contain macroscopic or microscopic metastatic masses. Upon opening the uterus the mole may be present in its original site. It is often necrotic, showing evidence

of infection and being more or less bathed in blood or pus. If the mole has been expelled, roughened, shaggy, necrotic particles may remain, or there may be a necrotic ulcer in the original situation of the mole. The character of the lesion may be suspected by examination of the discharged material. "The occurrence of great variations in the size of the vesicles, with many small opaque coherent nodules in the material which comes away in fragments with difficulty and in rather reduced amount, is suggestive" (Ewing). In early cases much of the uterine mucosa may be normal. The perforative tendencies of this tumor is one of its chief characteristics.

Histologically.—An atypical proliferation of both epithelial layers of the villus and its stroma is present.

The Langhans' cell may be greatly reduplicated, many layers being present; these, however, are definitely separated from the syncytium. Syncytial buds are large and numerous and syncytial wandering cells are increased in number. Metastases which are relatively infrequent and prone to be pelvic in location may be observed in the vaginal wall as vascular reddish nodules composed chiefly of syncytial cells. Their presence does not necessarily indicate a fatal termination, and records of cases have been reported which have survived after excision

of large vaginal metastases. Pulmonary metastases are less common and generally fatal.

The chorioadenoma is always preceded by a mole and most often occurs in multiparæ who are over forty years of age. Curtis and Oui [22] found the mole *in situ* in thirteen cases, it having been expelled in ten. After the expulsion of the mole there is a period, varying from a few days to a month or more, in which the bleeding is checked or ceases, and is followed by a resumption of the hemorrhage. In cases in which there has been a definite period of absence of bleeding, lasting for a month or more, the recurrence is often attributed to the onset of a normal menstrual period.

The bleeding is generally menorrhagic in type, tends to become more marked, and may either be continuous or the hemorrhages may be separated by intervals of cessation of flow. The bleeding is generally distinctly progressive and continuous until the termination of the disease.

In Curtis's fourteen cases, three terminated fatally and eleven recovered following panhysterectomy. Curettage has resulted in cure and reference has been made to one of our own cases in which, though it appeared inoperable after opening the abdomen, the tumor disappeared after irradiation with radium.

Choriocarcinoma (Ewing).—This is the most malignant of all the chorionic tumors. The original tumor may be small and the uterus not greatly enlarged. Choriocarcinoma generally springs from the placental site, is bluish red in color, and may be definitely differentiated from the adjacent myometrium with the naked eye. It also presents marked penetrating tendencies. On section the neoplasm is highly vascular, friable, reddish, the surface often being necrotic. Metastases occur early and are widespread, the lungs, liver, kidney, vagina, brain, and other structures possibly being involved. The metastatic lesions may be more massive than the primary growth. Metastases in the lung may simulate pulmonary tuberculosis. Metastases occur chiefly by the blood stream.

Histological.—The tumor consists of bands and masses of acidophile syncytium commingled in disorderly relations with islands of actively growing Langhans' cells, the stroma of the villi being absent. Huge masses of syncytial cells, often containing large cells possessing vesicular nuclei, may be present. Mitosis is limited to the Langhans' cells (Ewing). Much pelvic invasion of the blood-vessels, sinuses, and myometrium, extreme vascularity and early and widespread metastasis, are characteristic of this variety.

The history in cases of choriocarcinoma is often

less characteristic than that of the destructive mole. This tumor usually follows shortly after mole, abortion, ectopic pregnancy, premature labor, labor at term, or occasionally may develop years later, hemorrhage being the chief symptom. Occasionally the disease is masked by puerperal infection (Curtis) or the chief manifestations may be the result of metastasis. Hemorrhage and its resulting sequelæ, cachexia, and symptoms resulting from metastasis, followed by a fatal termination, is the common history, while hemorrhage, embolism, cerebral lesions, or peritonitis are the common causes of death. Ewing states that he has been unable to find a record of a recovery. When metastases have developed even the most radical operation will not help. The danger of dissemination as a result of the trauma incident to hysterectomy is a real one.

Syncytioma.—Syncytial Endometritis (Ewing) and Atypical Chorioma of Marchand.—This is a transitional variety in which the uterus is enlarged. On opening the endometrial cavity it may be found more or less filled with a vascular, friable, reddish, or necrotic new growth which is polypoid in outline.

Histologically.—Varied histologic pictures are observed. In general there is an absence of proliferation of the Langhans' cells or these represent a far smaller proportion of the tumor substance than in the former varieties.

Syncytioma may follow any form of pregnancy or such history may be lacking. Metrorrhagia is the most frequent symptom. Endometritis and metritis are common accompaniments and many cases die of infection. The uterus contains masses of necrotic tissue which have been mistaken for sarcoma. In Teacher's (quoted by Ewing) statistics of 188 cases there were 65 recoveries, but some were doubtless reported prematurely. Recovery has followed curettage and other manifestly incomplete forms of removal, although in considering the percentages of recoveries the possibility of mistaken histologic diagnosis must be taken into consideration.

My own experience is that, whereas there are many tumors which conform to the foregoing classification, there are also many which it is difficult definitely to place. Ewing himself has stressed the existence of these overlapping types, and many pathologists not only fail to recognize the foregoing classification, but, as previously stated, they believe the microscopic examination of these tumors to be of no aid whatsoever in their diagnoses. In general, it is the opinion of pathologists that the activity and degree of proliferation of the Langhans' cells is, to some extent at least, a guide to the degree of malignancy which is present, and this has been our own experience. We have observed one case of a destructive placental mole which had perforated through

all the layers of the uterine wall and caused intraperitoneal hemorrhage, which was cured by irradiation. In this specimen only a moderate proliferation of the Langhans' cells was present. Two other and apparently early cases of typical choriocarcinoma which were treated by radical hysterectomy were followed by early and widespread metastases and death. In both these cases the activity of the Langhans' cell was the chief histologic feature. As previously stated, attempts to correlate the grade of malignancy with the histologic character in tumors of chorionic origin have by no means been universally satisfactory. These tumors are not common and many pathologists have not had the opportunity of studying large series of specimens nor, more especially, of correlating these findings with the clinical course of the disease. Normal syncytial cells present many of the characteristics of malignant cells, they penetrate freely, are irregular in size, are more or less irregular in shape, and the nuclei stain deeply. It must be remembered that one of the chief functions of the trophoblast is the destruction of the tissue of its host (maternal tissue). The erosion of blood-vessels is essential in order to secure a blood-supply for the ovum. Morphologically and biologically the fetal cells are similar to those present in hydatidiform moles and in chorioepithelioma. Hence, in establishing the histologic

diagnosis of chorioepithelioma, the pathologist is deprived of many of the most important criteria upon which the recognition of malignancy in other varieties of tumor is based. At best, the histologic diagnosis of chorioepithelioma from fragments of the tumor is likely to be difficult; in some instances it is impossible. This is especially true in the case of curettings when one is without the knowledge that an actual neoplasm is present. It is probable that many unnecessary operations have been performed and many uteri sacrificed as the result of an incorrect interpretation of the histologic picture produced by curetting from cases of ordinary abortion and the minor grades of benign moles. Some cases are clearly malignant, but in many the pathologist can offer but little help to the clinician. This difficulty in differentiating malignant from benign chorionic tumor by histologic examination based upon fragments of the tumor or curettings is not generally recognized. Thus the careful pathologist who gives a guarded diagnosis may be severely and unjustly criticized. Marchand, Aschoff, Zagorianski, Kissel, von Franque, Albrecht, Hormann, and Hilschmann and Cristofoletti [23] stress this opinion. A history of recent pregnancy is usually present. The disease may follow any variety of gestation either normal or abnormal, either premature or at

term, or occasionally it occurs many years later. An explanation of these cases which occur at long intervals after the pregnancy may be found in the fact that benign placental polypi may exist for years. Furthermore, in certain cases apparently viable syncytial cells may be found in the myometrium. This is true even in the aged. However, the majority of cases develop within the four months following gestation. Walthard [24] records the history of a case in which metastases became evident in the eighth month of a supposedly normal pregnancy. Polano [25] and others have recorded the histories of cases in which the latent period has existed for many years. A mole is known to have been present in a third to one-half of the cases. The combined stastistics of Teacher [1] and Polloson and Violet,[26] which comprise 637 cases, show that chorioepithelioma was preceded by

Hydatid mole 276 times, or 40.8 per cent
Abortion 144 times, or 30.5 per cent
Pregnancy at term 148 times, or 24.5 per cent
Extrauterine pregnancy 19 times, or 3.4 per cent

The Fallopian tube is a rare site for the development of chorioepithelioma, although a number of cases have been observed. The symptoms are those of tubal pregnancy, and recurrence is prone to develop after operation. Sunde has recorded the history of a case of chorioepithelioma which arose from an ovarian pregnancy. For literature on this

subject see the papers of Solomons and Smith [27] and Risel.[28]

Chorioepithelioma is more common in multiparæ and in women past forty years of age. Hemorrhage is the chief symptom, and this may take almost any form, but is metrorrhagic in type, rapidly progressive, and often tends to follow trauma as well as appearing at other times. A dark grumous, occasionally malodorous discharge is often present during the intervals of active bleeding, which are soon followed by anemia, cachexia, and loss of weight and strength. The evolution of the symptoms is rapid. All local symptoms may be overshadowed by those produced by distant metastatic lesions, which may be more massive than the primary tumor. Evidence of a low-grade infection is common. Because of the erosive properties of the chorionic epithelioma, tumor-cells usually find their way into blood-vessels and are borne to distant localities. Here they still retain their erosive character, with the result that local hemorrhages occur. Metastatic pulmonary and vaginal lesions are among the most frequent. Between the symptoms resulting from the most malignant types all gradations exist. It is doubtless true that some of the more benign variations are never recognized, being diagnosed only as abortion. The association of sep-

sis, peritonitis, and other manifestations of infection is frequent.

Mention has already been made of cases in which the symptoms resulting from the primary tumor were overshadowed by those resulting from a more massive metastasis. Thus pulmonary metastasis is prone to result in hematemesis and, with the loss of weight and strength, may simulate rapidly advancing pulmonary tuberculosis. The vaginal bleeding attendant upon such a condition may be mistaken for an associated abortion. Erck and Outerbridge [29] have recorded the history of a case which suggested a ruptured extrauterine pregnancy. Massive intraperitoneal hemorrhage, resulting from erosion into a large blood-vessel and through the entire thickness of the uterine wall, is occasionally an early symptom. Metastasis to the brain may produce hemiplegia or some other manifestation of a cerebral lesion.

Examination.—Evidence of a recent pregnancy is generally found, while vaginal metastasis, manifest as bluish-red nodules often occurring on the posterior wall, are not infrequent. The cervix is softened and the canal patent. The body of the uterus is enlarged, often in retroposition, and is soft and moderately symmetrical in shape. The adnexa may be normal. Cottalorda found bilateral luetien cysts present in 9.4 per cent. of cases, and [30] other

investigators have recorded their presence with greater frequency. Thus Fohr and Kratzeisen[31] found them present in 50 per cent of cases. From a study of the literature and my own experience it would seem that lutein cysts, of sufficient size to be recognized by bimanual vaginal examination, are present in less than 10 per cent of the cases.

Diagnosis.—The recurrence of bleeding after the expulsion of a mole, or after a period of amenorrhea following an abortion; the rapid increase and persistence in the bleeding, out of proportion to what would be expected from such a condition; recurrence of bleeding following a curettage for incomplete abortion, especially if there is reason to believe that the uterus was thoroughly emptied; a mild grade of infection; and the enlargement of the uterus, which may be attributed to retained secudines or subinvolution—are suggestive of the presence of a chorioepithelioma. Anemia, loss of weight and strength, and later the development of vaginal or pulmonary metastases, together with the rapid evolution of symptoms, point clearly to the presence of a chorioepithelioma in the typical case. The early development of massive and distant metastases may occasionally cause confusion in the diagnosis, as may well-marked symptoms of sepsis. Many cases of this disease have been mistaken for infection following abortion.

Prognosis.—There is no neoplasm in which the outcome is more difficult to foretell than in this one. Apparently early chorioepithelioma which has been submitted to the most radical form of removal may be followed by early and widespread metastasis and death, whereas other seemingly similar but more advanced tumors have been known to undergo spontaneous resolution. Cure of this tumor has followed such incomplete operation as curettage or other methods of partial removal. Furthermore, histologic examination of the tumor is by no means an accurate prognostic guide. In typical cases the experienced pathologist may render valuable assistance in certain cases, but, on the other hand, specimens may be encountered in which the grade of malignancy cannot be determined.

Treatment.—Provided the diagnosis of chorioepithelioma has been established, radical hysterectomy by the abdominal route, followed by deep X-ray therapy, probably offers the best hope of a permanent cure. The rarity of the tumor, which makes studies of the end results in series of cases difficult, the wide variation in the degree of malignancy, and the frequent inability of even the experienced pathologist to render definite aid in the grading of specimens, all mitigate against careful end-result studies, thus making very difficult the accurate comparison of results secured by various

methods of treatment. It is probable that some of the cures which have been recorded are the result of benign conditions being mistaken for this relatively rare tumor. This, however, does not explain all such results. Spontaneous cures and complete resolution following incomplete operation have been recorded by such experienced pathologists as Pick and others. For these reasons it is unsafe to draw conclusions from isolated cases, for, as shown, recovery may follow incomplete removal. Because of their embryonal character it appears likely that these tumors would be susceptible to irradiations by both radium and X-ray. Mention has already been made of one personal case which was successfully treated by radium, and numerous others have been recorded. If radical operation is contra-indicated on account of the condition of the patient or the advanced stage of the tumor, irradiation is worthy of a further trial. In this connection the danger of dissemination, resulting from the trauma incident to operation, should also be considered. The value of irradiation is still unproven.

Results.—In the early literature pertaining to this tumor it is probable that only the malignant types were recognized, or at any event it was they that attracted the chief attention. Thus, all of Sanger's five cases succumbed within a short period, and thirty-five years ago Apfelstaedt voiced the

opinion that all treatment was useless. In 1902, however, Polano reported 50 per cent of cures and Teacher's series showed 63.3 per cent of salvage. Many other more recent reports, however, present less satisfactory results. Recurrence generally becomes manifest in less than a year and death soon follows.

REFERENCES

[1] Teacher, *Jour. Obst. & Gyn., Brit. Emp.*, 1903, p. 4.
[2] Ewing, J., *Neoplastic Disease*, Philadelphia and London, 1919, p. 546.
[3] Geist, *Surg., Gyn., & Obst.*, 1921, vol. xxxii, p. 427.
[4] Wolfe, S. C., *Am. Jour. Obst. & Gyn.*, 1929, vol. xvii, no. 6, p. 826.
[5] Bremser, J. G., *Über Lebende Würmer in lebenden Menschen*, Wein, 1819.
[6] Boivin, Mme., *Repert. Med. et Chir. et Obst.*, Brussels, 1837, vol. ii, p. 427.
[7] Findley, P., *Jour. Am. Med. Assoc.*, 1904, vol. xliii, p. 1351.
[8] Molitor quoted by Novak, E., *Jour. Am. Med. Assoc.*, 1922, vol. lxxviii, p. 1771.
[9] Essen-Moller, *Zeit. f. Gynäk.*, 1917, vol. xli, p. 781.
[10] Jonas, *Deuts. Med. Wochenschr.*, 1914, vol. xl, p. 1799.
[11] Broadhead, *Am. Jour. Obst. & Gyn.*, 1922, vol. iii, p. 655.
[12] Frank, R. T., *Practice of Surgery*, 1928, vol. xi, chap. 20, p. 5.
[13] Pick, L., *Berl. Klin. Wchnschr.*, 1904, vol. xl., p. 158.
[14] Fruhinsholz, A., *Gynec. et Obst.*, 1928, vol. xviii, p. 193.
[15] Schumann, E. A., *Am. Jour. Obst. & Gyn.*, 1922, vol. iv, p. 386.
[16] Bland, P. B., *Am. Jour. Obst. & Gyn.*, 1928, vol. xv, p. 390.
[17] Greenhill, J. P., *Am. Jour. Obst. & Gyn.*, 1929, vol. xvii, no. 5, p. 742.
[18] Vokmann, R., *Virchow's Archiv.*, 1867, p. 61.
[19] Sanger, M., *Arch. f. Gyn.*, 1893, vol. xliv, p. 89.
[20] Sunde, *Zentralb. f. Gynäk.*, 1922, vol. xiv, p. 875.
[21] Hitschmann, F. A., and Cristofoletti, R., *Wein Klin. Wochenschr.*, 1911, vol. xxiv, p. 655.

[22] Curtis and Oui, *Annal. de Gynéc*, 1913, vol. lxx, p. 220.

[23] Quoted by Graves, W. P., *Gynecology*, Philadelphia and London, 1928, p. 437.

[24] Walthard, *Zentralbl. f. Gynäk.*, 1905, vol. xxix, p. 385.

[25] Polano, *Ztschr. f. Geburtsh. u. Gynäk.*, 1913, vol. lxxv, p. 149.

[26] Polloson et Violet, *Am. de Gyn. et d'Obst.*, 1913, vol. xl, p. 5.

[27] Solomons, B., and Smith, E. C., *Jour. Obst. and Gyn., Brit. Emp.*, 1923, p. 162.

[28] Risel, W., *Verhandb. d. deuts. Path. Gesellsch.*, Jena, 1914, vol. xvii, p. 386.

[29] Erck, T. A., and Outerbridge, G. W., *Internat. Clin.*, 1915, pp. 25, 50, 203.

[30] Cottalorda, J., *Gyn. et Obst.*, 1921, pp. 4, 119.

[31] Fohr, O., and Kratzeisen, E., *Arch. f. Gyn.*, 1923, pp. 118, 220.

INDEX

Adenoacanthoma, 33
Adenocarcinoma, 29, 33, 82, 123
Adenofibromyxochondrosarcoma, 210
Adenoma malignum, 82
Adenomyoma, 7, 40, 118, 147, 180
  circumscribed, 183
  diffuse, 184
Adnexitis, 154
Alveolar sarcoma, 209
Anemia, 133, 158, 174
Angiosarcoma, 209
Appendectomy, 169

Biopsy, 33, 39, 40

Cancer susceptibility, 18
Carcinoid, 215
Carcinoma, epidermoid, 29
  glandular, 29
  of body of uterus, 78
  of cervical stump, 65
  of cervix, 10
  with pregnancy, 62
Carcinosarcoma, 10, 83, 211
Cauliflower cervical carcinoma, 23
Cervical polyp, 1
Cervical sarcoma, 198
Cervicitis, 13, 15, 34, 78
Cervix, carcinoma of, 10
  fibromyoma of, 7
  irritation of, 13
  laceration of, 13, 49
Cervix—(*Continued*)
  lymphatics of, 26
  repair of, 16, 49
  stenosis of, 16
  tuberculosis of, 40
Chorioadenoma destruans, 232
Choriocarcinoma, 235
Chorioepithelioma, 230
Clark method for fluctuation, 143
Clark test, 98, 201
Climacteric after radium, 163
Constipation, 135
Curettage, 64, 91, 159, 227
Curettings, preparation for examination, 94

Discharge, 4, 8, 35, 86, 134, 200

Embolism, 119
Endometrial polyp, 90, 189
Endometrial sarcoma, 199
Endometrioma, 129
Endometritis, 78, 84
Endothelioma, 75, 212

Fibromyoma, of cervix, 7
  of uterus, 89, 110
Fistula, vaginal, 25, 55
Frozen section, 93

Hemorrhage, 34, 85, 131, 227
Heredity, 18
Hydatidiform mole, 220

Hydronephrosis, 135
Hysterectomy, 8, 53, 64, 104, 229
Hysteromyomectomy, 169
Hysterotomy, 229

Idiocy, 63
Interstitial cervical carcinoma, 21, 25
Irritation, chronic, 11, 79

Law of Bergonie and Tribondeau, 29
Lead treatment, 202
Leucorrhea, 4, 8, 35, 86, 134, 200
Lipoma, 216
Lipomyosarcoma, 210

Malignancy index, 32
Malignant degeneration, of myoma, 73, 121, 205
of polyp, 2, 73, 90
Melanosarcoma, 73, 210
Menorrhagia, 35, 131
Metrorrhagia, 34
Metrorrhagic myopathy, 90
Myoma uteri, 89, 110
degenerative changes in, 120, 136
sarcomatous changes, 121
Myomectomy, 8, 157, 165
Myometrial sarcoma, 202
Myxosarcoma, 72

Nabothian cyst, 25

Ovarian grafts, 173

Papillary cervical carcinoma, 21, 23
Perforation of uterus, 81
Periodic medical examination, 51
Perithelioma, 72, 215
Pneumoperitoneum, 146
Polypectomy, 6
Polypus, cervical, 1
endometrial, 90, 189
Pregnancy, 26, 45, 62, 138, 178
Prophylaxis of cancer of cervix, 49
Pruritus, 135

Radiosusceptibility, 32, 68
Radium therapy, 29, 56, 101, 105, 149, 175
Repair of cervix, 16, 149
Rhabdomyosarcoma, 210
Salpingitis, 128
Sarcoma, alveolar, 209
angiosarcoma, 209
botryoides, 199
cervical, 198
endometrial, 199
myometrial, 202
of cervix, 72
of uterus, 114, 196
Sarcomatous change in myoma, 121, 205
Spinal cell carcinoma, 30, 33
Spindle cell carcinoma, 30, 33
Spiroptera neoplastica, 15
Stenosis of cervix, 16
Sympathoma, 215
Syncytioma, 236
Syphilis of cervix, 40

Test, Clark, 98, 201
Thrombosis, 119
Torsion of myoma, 137
Transitional cell carcinoma, 30, 33

Tuberculosis of cervix, 40

Ulcerative cervical carcinoma, 21

Vaginal fistula, 25, 55

Vaginitis, senile, 90

Womb stones, 117

X-ray therapy, 66, 104, 145, 149, 175